

## Self-Treatment with Dental Implants

Osama Abu-Hammad<sup>1\*</sup>, Mahmoud Al Omiri<sup>1</sup>, Mohammad Hammad<sup>1</sup>, Ahmad Abdelaziz Mahmoud<sup>1</sup>, Najla Dar-Odeh<sup>1</sup> and Ahmad Kutkut<sup>2</sup>

<sup>1</sup>Faculty of Dentistry, University of Jordan, Amman, Jordan

<sup>2</sup>College of Dentistry, University of Kentucky, Lexington, USA

### Abstract

**Background:** Many self-treatment dental procedures have been reported in the literature including extractions and fillings.

**Findings:** This case report describes the clinical procedure of dental implantation and subsequent prosthetic treatment that a dentist performed to him starting from the local anesthetic injection and finishing with cementation of a fixed prosthesis.

**Conclusions:** Ethical and safety guidelines and standards of related procedures of the dental profession need reviewing to take in consideration controversial aspects of self-treatment.

**Keywords:** Self-treatment; Dental implantation; Local anesthesia

### Introduction

Whereas the term “self-treatment” indicates mainly the use of medications, self-treatment also applies, to a lesser extent, to do-it-yourself (DIY) treatment. DIY has been recognized in dental practice since the dawn of history. Attempts of tooth extraction, constructing and adjusting prosthetic appliances and teeth whitening have been documented and reported in the literature [1]. Perhaps the most frequently reported DIY dental procedure is tooth extraction [2]. In the past, some people resorted to the string and door knob to pull the tooth. Surprisingly, this procedure is still reported even in well-developed countries [3]. Other more bizarre dental DIY procedures were also reported in recent times like the construction of a primitive prosthetic device to replace upper anterior teeth and again this took place in a developed part of the world [4].

However, self-treatment becomes less prevalent when surgical intervention is required, particularly if the intervention was complex in nature. Simple oral surgical procedures that may be performed in a DIY style may include draining abscess and excision of warts.

This case report is presenting for the first time self-treatment with dental implants carried out by a qualified dentist under local anesthesia, although the same dentist has a history of self-extractions of some of his teeth.

### Case Report

The dentist is 56 years old with a long experience in implant dentistry spanning 14 years with the installation of more than 12000 implants. His experience includes 8 different dental implant systems. The dentist for the last 10 years used panoramic dental radiographic examination for the diagnostic purposes of his patients.

The dentist had a bridge in the lower left quadrant with a symptomatic distal abutment. The dentist obtained a panoramic radiograph for himself (Figure 1) prior to the operation that showed a missing lower left first molar tooth restored with a bridge gaining support from the second premolar and second molar teeth. The second molar tooth was root canal treated but was tender on function and percussion.

The radiograph indicated also the available bone height. The dentist used bi-digital examination of his edentulous ridge to estimate available bone width to decide on the proper diameter of the implant.

As the ridge was wide enough, the decision was to carry out flapless operation (without elevating a gingival flaps prior to the drilling the implants' sockets).

There were three assistants helping with the procedure: one holding a mirror for the operator-patient, another performing the suction and the third helped handing the required armamentarium and implants.

The dentist administered for himself an inferior dental block with buccal infiltration with a local anesthetic (2% Lidocaine with 1:80000 Epinephrine) (Figure 2). The dentist removed the existing bridge and extracted the lower left second molar tooth.

The dentist decided to carry out flapless implantations in the lower left first molar region and an immediate implantation in place of the second molar tooth socket. Flapless implantation entailed the drilling of implant beds through the gingiva without raising a gingival flap. After the preparation of two implant beds at the required depths in the regions of lower left first molar tooth (Figures 3 and 4), the dentist inserted three implants. The implants were single body implants that left the abutments exposed. Bone quality and quantity in the extraction socket of the lower left second molar tooth was not ideal for the insertion of an implant.

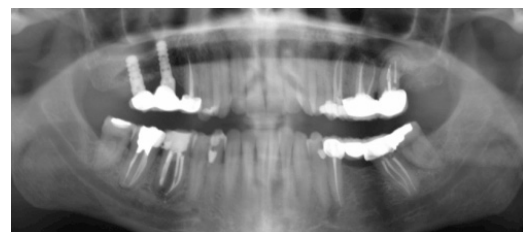


Figure 1: Operation that showed a missing lower left first molar tooth.

**\*Corresponding author:** Dr. Osama Abu-Hammad, Professor, Faculty of Dentistry, University of Jordan, Amman, Jordan, E-mail: [o.abuhammad@yahoo.com](mailto:o.abuhammad@yahoo.com)

**Received** October 08, 2012; **Accepted** October 22, 2012; **Published** October 24, 2012

**Citation:** Hammad OA, Omiri MA, Hammad M, Mahmoud AA, Odeh ND, et al. (2012) Self-Treatment with Dental Implants. Dentistry 2:148. doi:10.4172/2161-1122.1000148

**Copyright:** © 2012 Hammad OA, et al. This is an open-access article distributed under the terms of the Creative Commons Attribution License, which permits unrestricted use, distribution, and reproduction in any medium, provided the original author and source are credited.

The lower left second premolar was previously prepared as it was the mesial abutment for the old bridge. An impression was made for the second premolar tooth along with the adjacent abutments of the installed implants. The prosthesis was fitted 3 days later over the tooth and the implants by the same dentist who also checked his occlusion and carried out necessary adjustments (Figures 5 and 6).

## Discussion

Dental implantation is a complex oral surgical procedure that requires a considerable amount of knowledge and training. To have the capability to perform this procedure in a DIY style has important and serious implications. This case report documents for the first time a case of DIY dental implantation of three implants placed at the same setting. When asked about the reasons behind his decision to do this procedure for himself, the dentist confirmed that it is not the lack of confidence in other surgeons; it is the over self confidence that motivated him to do so. It was mentioned previously that this dentist has a history of DIY dental extractions, and an exceptionally long history of successful dental implantation of more than 12,000 implants.

Another intriguing aspect of this case is that the simple technique of plain radiography, the panoramic radiograph, was the only diagnostic method used in addition to clinical examination. None of the advanced diagnostic methods that facilitate proper placement of the implant were used; such methods include CT scans and the use of custom made surgical guide via stereolithography which are available in the country.

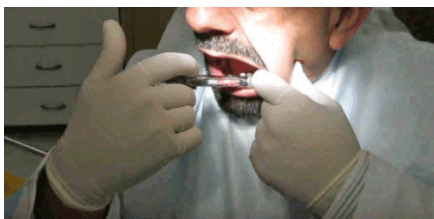


Figure 2: The dentist administered for himself an inferior dental block with buccal infiltration with a local anesthetic.

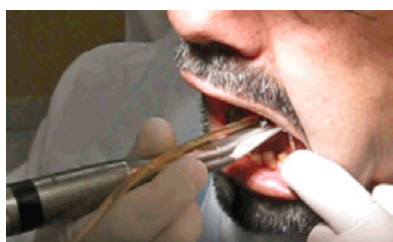

Figure 3: Implant beds at the required depths in the regions of lower left first molar tooth.

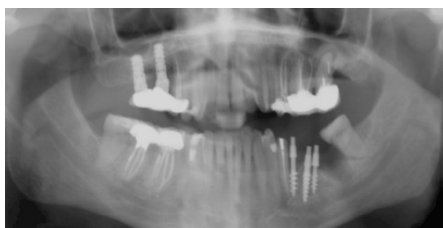

Figure 4: Implant beds at the required depths in the regions of lower left first molar tooth.

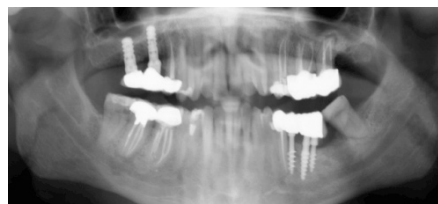


Figure 5: Prosthesis was fitted 3 days later over the tooth and the implants.

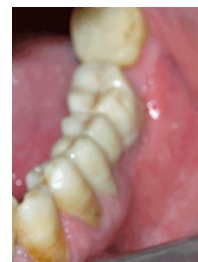

Figure 6: Prosthesis was fitted 3 days later over the tooth and the implants.

There are various dental implant systems on the market with different indications. The used implants were single body immediate loading implants. These entail the fitting of the prosthesis after short time of the installation procedure.

Although three dental assistants were available at the surgery, however, had a complication arisen; no one could have interfered efficiently and safely. Dental implantation is not a procedure without complications. A number of intrasurgical complications may arise, including hemorrhage, mandibular fracture, and nerve damage. It is recommended that the presence of another qualified dental surgeon was mandatory to guarantee safety of the procedure. The fact that this procedure was performed in a dental center where many dentists were working at the same time, including an oral surgeon, makes such a procedure more safe.

An important question that should be asked here, "If the dentist is performing any dental procedure for him- or herself, does this absolve this dentist from the legal responsibility in case complications arise?"

Throughout history unfortunate incidents happened to clinicians practicing their skills on themselves or experimenting, either for self satisfaction or for the sake of their patients. Although some of this work might add a lot to science, lessons should be learned, to prevent tragic incidents that may unfortunately hurt those people like what happened with: "Horace Wells" who introduced general anesthesia through his work and paid his life for that.

Actually, sometimes it might be beneficial to educate and train people in certain cases of emergency i.e. a lady delivering her baby alone, or a subject having a heart attack. However, if there is no emergency this sort of practice should be discouraged as it might be accompanied with increased chance of complications especially if the operator is not highly experienced.

## Acknowledgement

We would like to thank Dr. Imran Ataya (Arab Dental Center, a private practice at Amman, Jordan) for providing us with his consent to report his self-treatment procedure as well as the video that documents this surgery.

## References

1. Jagger DC, Harrison A (1996) DIY dentures--a case report. Br Dent J 180: 221-222.

2. Curtis EK (1990) The string and the doorknob: profile of a popular approach to dental extraction. *J Oral Maxillofac Surg* 48: 1084-1092.
3. Oliver R (2000) An unusual case of self-treatment. *Br Dent J* 188: 60.
4. Egemonye V (2004) DIY dentistry UK style. *Br Dent J* 196: 312.