

# PNH in a Child with Ringed Sideroblast-Diagnostic Riddle

Richa Juneja\*, Gurpreet Kaur Sagoo, Priyanka Mishra, Renu Saxena

Department of Hematology, All India Institute of Medical Science, New Delhi, India

## ABSTRACT

Paroxysmal nocturnal hemoglobinuria (PNH) is a rare acquired stem cell disorder presenting either with hemolytic or thrombotic event or co exists in patients with aplastic anemia and Myelodysplastic syndromes (MDS). These PNH clones have been shown to have prognostic and therapeutic implications. Flow cytometric analysis of GPI-linked proteins is the method of choice for diagnosis and it has replaced the acidified-serum lysis test (Hams test) and sucrose lysis test being quantitative and a more sensitive method. Occurrence of this PNH clones in pediatric patients is rare (10%) with few studies being reported. It can have varied clinical and haematological manifestations and should be considered in children especially in the setting of bone marrow failure causing cytopenia. We hereby present a rare case of child having hemolytic manifestation of PNH with cytopenias and unusual marrow findings. We are reporting this case because of the rarer presentation of an uncommon disorder and to highlight that though rare but PNH should be considered in a child with bone marrow failure, unexplained hemoglobinuria and thrombosis at unusual sites.

**Keywords:** Paroxysmal nocturnal hemoglobinuria; Flow cytometry; hemolysis; bone marrow failure

## INTRODUCTION

PNH is an extremely rare childhood disease and affects the precursor hematopoietic cells with an acquired somatic mutation of the PIGA (Phosphatidylinositol glycan class A) gene [1]. First described in the 19th century the classical triad of PNH includes hemolytic anemia recurrent thrombosis and impaired bone marrow function, these three impairments can be seen in different ratios and severities [2]. PIGA gene is located on the X chromosome, in defective synthesis the levels of CD55 (delay accelerating factor) and CD 59 (membrane inhibitor of reactive lysis) is markedly reduced and this makes the cells susceptible to complement mediated lysis.

## CASE PRESENTATION

A 14 years old male presented with weakness, yellow discoloration of eyes and abdominal pain for 3 weeks. On examination pallor and icterus were noticed. He did not have any organomegaly or lymphadenopathy. On basic investigations CBC revealed pancytopenia with Hemoglobin -77 g/l, total leucocyte count  $-2.8 \times 10^9 /l$  and platelet count  $-90 \times 10^9 /l$ . Peripheral smear

confirmed CBC findings with normocytic normochromic RBC morphology and Polychromatophils. No spherocytes, sickle cells, bite cells on peripheral smear. Liver function test showed elevated bilirubin of 15.8 mg/dl with 11.5 mg/dl unconjugated component and high corrected reticulocyte count of 11%. Kidney function test was within normal limit. There was no radiological evidence of thrombosis. No obvious cause of abdominal pain was detected.

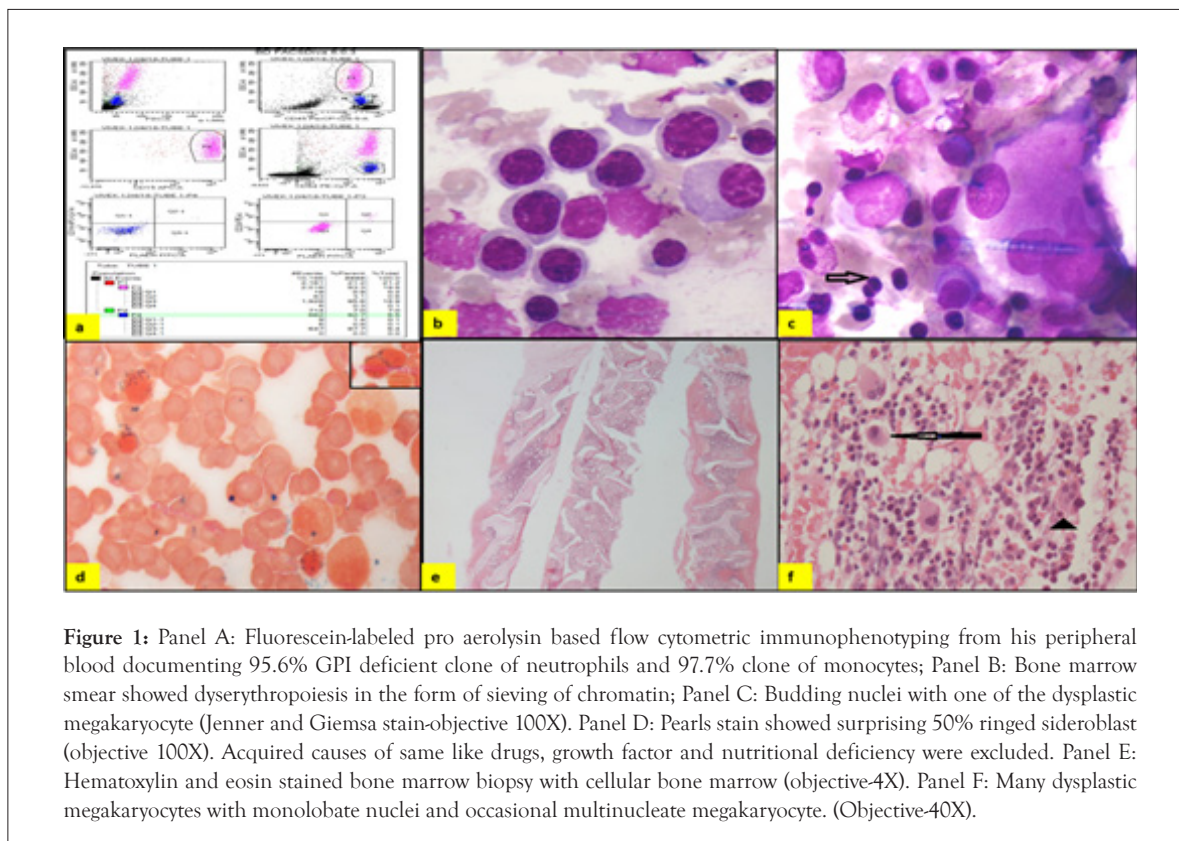
With High reticulocyte count, unconjugated bilirubinemia hemolytic anemia work up was ordered. His G6PD levels were normal, direct Coombs test was negative and the HPLC was normal. In view of above features and inconclusive hemolytic work up, test for paroxysmal nocturnal hemoglobinuria (PNH) was initiated. Flow cytometry based testing on blood showed large PNH clone >95% of granulocytes and monocytes being deficient for GPI linked markers like FLAER and CD14, CD25 (Figure 1 panel A). Bone marrow test was done which showed surprising findings of multilineage dysplasia with 50% ring sideroblast as summarized in Figure 1 panel B-F. A Final diagnosis of PNH in the setting of MDS with multilineage dysplasia with ring sideroblast (MDS-MLD with RS) was made.

**Correspondence to:** Richa Juneja, Department of Hematology, All India Institute of Medical Science New Delhi, New Delhi, India, Tel: 919643302635; E-mail: drrichajuneja@gmail.com

**Received:** September 24, 2021, **Accepted:** October 08, 2021, **Published:** October 15, 2021

**Citation:** Juneja R, Sagoo GK, Mishra P, Saxena R (2021) PNH in a Child with Ringed Sideroblast-Diagnostic Riddle. J Blood Disord Transfus. 12: 479

**Copyright:** © 2021 Juneja R, et al. This is an open-access article distributed under the terms of the Creative Commons Attribution License, which permits unrestricted use, distribution, and reproduction in any medium, provided the original author and source are credited.



**Figure 1:** Panel A: Fluorescein-labeled pro aerolysin based flow cytometric immunophenotyping from his peripheral blood documenting 95.6% GPI deficient clone of neutrophils and 97.7% clone of monocytes; Panel B: Bone marrow smear showed dyserythropoiesis in the form of sieving of chromatin; Panel C: Budding nuclei with one of the dysplastic megakaryocyte (Jenner and Giemsa stain-objective 100X). Panel D: Pearls stain showed surprising 50% ringed sideroblast (objective 100X). Acquired causes of same like drugs, growth factor and nutritional deficiency were excluded. Panel E: Hematoxylin and eosin stained bone marrow biopsy with cellular bone marrow (objective-4X). Panel F: Many dysplastic megakaryocytes with monolobate nuclei and occasional multinucleate megakaryocyte. (Objective-40X).

He was given supportive treatment in the form of folic acid supplements and was managed with androgen and steroid due to non-affordability for complement blocker eculizumab. He showed good response and is under regular follow up.

## DISCUSSION

PNH is a rare disorder presenting as chronic intravascular hemolytic anemia. It is the only hemolytic anemia resulting from a membrane defect that is not inherited. Though CD55 and CD59 are the most important antigens that result in complement mediated lysis till date over 20 different antigens (CD16, CD24, CD52, CD55, CD59, CD58, CD66b/67, CD73, CD87, CD90, CD108) have been described that are absent on PNH cells [2]. Platelets and granulocytes also have reduced GPI proteins and therefore these patients have increased predisposition to infections and thrombosis. PNH is classified as classical form, PNH in the setting of specified marrow disorder and sub clinical PNH [3]. Classical form of PNH present with hemolytic or thrombotic manifestation with cellular bone marrow showing trilineage hematopoiesis. 20 to 30% of aplastic anemia and low grade MDS cases presenting with clinical features of marrow failure (cytopenias) can show small PNH clones. However, it is less often reported in MDS with ringed sideroblast morphological category. Also such cases of PNH in the setting of bone marrow failure disorder usually have small clones unlike our case showing >95% clone size. Both the diseases namely PNH and myelodysplasia usually affect adult age group. Ware et al studied patients less

than 21 years over a 25 year period. They found a lesser incidence of hemoglobinuria and a higher incidence of bone marrow failure at presentation [4]. Another study from Netherlands by van den Heuvel-Eibrink et al describes PNH in 11 pediatric patients with secondary PNH, 7 associated with AA and 4 with MDS [5]. Other reports include lesser number of patients [2-4] or are restricted to case reports only [6,7]. While Thrombosis and infections are the main causes of mortality in adults the risk of thrombosis has been found to be lower in children than adults. PNH clones appear frequently in patients with MDS and AA which may even evolve into classic PNH. It has been described as cases of clonal evolution from AA; and at the end, acute leukemia (AL) has rarely been described [8] With aplastic anemia/PNH, PNH can occur before, at the same time, or after the aplastic anemia is detected. With MDS/PNH, usually it's PNH occurring beforehand or at the same time. PNH does not generally develop after an MDS diagnosis. PNH can present with MDS, but that is a much rarer occurrence. There are some features of PNH that can be confused with MDS, such as the fact that patients with PNH often also have a hypercellular marrow, and 25% of patients with PNH can have a chromosomal abnormality [9].

## CONCLUSION

This is an unusual case of pediatric PNH presenting with both hemolysis and marrow failure and showing multilineage dysplasia with ring sideroblasts in bone marrow. Possibly it is a case of PNH in the setting of primary bone marrow disorder. This case

was indeed a diagnostic riddle. However due to cost constraints molecular studies could not be performed to look for SF3B1 splicing mutation commonly associated with MDS cases showing ring sideroblast. This case highlights the well-known connectivity in spectrum of marrow failure syndrome namely aplastic anemia/MDS and PNH. however projects unusual finding of ringed sideroblast and large clone size in such scenario.

## FOOTNOTES

**Conflicts of interests:** The Authors declare that there are no competing interests.

**Sources of support:** Nil

## REFERENCES

1. Halder R, Mishra P, Aggarwal M, Mannivanan P, Dhawan R, Seth T, et al. Outcomes of paroxysmal nocturnal hemoglobinuria in the pediatric age group in a resource-constrained setting. *Pediatr Blood Cancer*. 2020;67(4): e27712.
2. Hillmen P, Richards SJ. Implications of recent insights into the pathophysiology of paroxysmal nocturnal haemoglobinuria. *Br J Haematol*. 2000;108(3): 470-9.
3. Kulagin A, Golubovskaya I, Ganapiev A, Babenko E, Sipol A, Pronkina N, et al. Prognostic value of minor PNH clones in aplastic anaemia patients treated with ATG-based immunosuppression: results of a two-centre prospective study: O426. *Bone Mar Transplant*. 2011;46.
4. Ware RE, Hall SE, Rosse WF. Paroxysmal nocturnal hemoglobinuria with onset in childhood and adolescence. *New Eng J Med*. 1991;325(14): 991-6.
5. Van Den Heuvel-Eibrink MM, Bredius RG, Te Winkel ML, Tamminga R, de Kraker J, Schouten-van Meeteren AY, et al. Childhood paroxysmal nocturnal haemoglobinuria (PNH), a report of 11 cases in the Netherlands. *Br J haematol*. 2005;128(4): 571-7.
6. Rizk S, Ibrahim IY, Mansour IM, Kandil D. Screening for paroxysmal nocturnal hemoglobinuria (PNH) clone in Egyptian children with aplastic anemia. *J trop ped*. 2002;48(3): 132-7.
7. Wainwright L, Brodsky RA, Erasmus LK, Poyiadjis S, Naidu G, MacKinnon D. Paroxysmal nocturnal hemoglobinuria arising from Fanconi anemia. *Pediatr Hematol Oncol J*. 2003;25(2):167-168.
8. Lopez Rubio M, Gaya A, Morado M, Carrasco V, Gonzalez Fernandez A, Villegas A. Relationship between myelodysplastic syndrome and paroxysmal nocturnal hemoglobinuria: Spanish erythropathology group and Spanish paroxysmal nocturnal hemoglobinuria working group experience. *Blood*. 2015; 26 (23): 4546.
9. Young NS. Paroxysmal nocturnal hemoglobinuria and myelodysplastic syndromes: clonal expansion of PIG-A-mutant hematopoietic cells in bone marrow failure. *Haematologica*. 2009;94(1):3.