

Aerococcus Viridians: Under-Recognized Cause of Pyomyositis

Antoine Abi Abboud¹, Sirine O. Ahmad^{2*}, Mohamad M. Habli³ and Chady Bechara⁴

¹Division of gastroenterology, Department of Internal Medicine, Lebanese University, Beirut, Lebanon

²Department of Internal Medicine, Lebanese University, Beirut, Lebanon

³Department of Internal Medicine, Saint George Hospital University of Balamand, Beirut, Lebanon

⁴Division of infectious diseases, Department of Internal Medicine, Lebanese University, Beirut, Lebanon

*Corresponding author: Sirine O. Ahmad, Department of Internal Medicine, Lebanese University, Beirut, Lebanon, E-mail: sirineahmad219@hotmail.com

Received date: Sep 5, 2016; Accepted date: Oct 12, 2016; Published date: Oct 20, 2016

Copyright: © 2016 Abboud AA, et al. This is an open-access article distributed under the terms of the Creative Commons Attribution License, which permits unrestricted use, distribution, and reproduction in any medium, provided the original author and source are credited.

Abstract

Introduction: Aerococcal infection is a rarely described pathogen in the literature. *Aerococcus* species may be isolated from urine, blood or other sources. Several sites of infection caused by aerococcal infection have been reported including arthritis, UTI, endocarditis and meningitis. However, to our knowledge there is not a single case of soft tissue infection caused by this germ.

Case presentation: We report a case of middle aged patient with multiple comorbidities, presenting with right supraclavicular mass following chest trauma. Imaging study showed multilobulated collection involving thoracic and neck muscles and invading the clavicle. Intraoperative drainage of the pus grew exclusively *Aerococcus viridans*.

Conclusion: *Aerococcus viridans* is unusual cause of soft tissue infection, but should be considered in the differential diagnosis when evaluating patients with suspected deep soft tissue infection. *A. viridans* infection is underestimated because of technical difficulties in the identification of this organism. The introduction of matrix-assisted laser desorption ionization time-of-flight mass spectrometry carried great success in accurate identification, as early identification of the offending organism guides physicians to appropriate treatment.

Keywords: Aerococcal infection; *Aerococcus viridans*; Pyomyositis; MALDI-TOF MS

Case Presentation

We present a 60 year old male patient who is known to have a long standing history of diabetes mellitus type 2 for more than 20 years, dyslipidemia and coronary artery disease that requiring percutaneous transluminal coronary angioplasty.

Patient presented to physician seeking for medical help and for evaluation of right supraclavicular mass. History goes back to 3 weeks prior to presentation when the patient sustained chest trauma in car accident. At that time patient underwent imaging studies to rule out fractures. No fractures or chest contusion was detected on standard chest X-ray. In the following days after trauma, patient started to sense unpleasant feeling at right subclavicular area associated with sensation of growing mass.

No documented fever or chills. No weight loss, nausea, vomiting or decreased per os intake.

Upon presentation patient was hemodynamically stable, afebrile and not in acute distress. Physical exam was non-contributory except for soft tender mass around the right clavicle with presence of crepitus, erythema and hotness.

Vital signs

Blood pressure: 110/70 mmHg; Temperature: 37.3; Heart rate: 87/min; Respiratory rate: 18/min

Laboratory findings on admission are shown in Table 1.

| WBC | Neutrophils | Hemoglobin | Platelets | CPK | SGP T | Creatinine | CR P |
|-------|-------------|------------|-----------|-----|-------|------------|------|
| 11000 | 77 | 12.5 | 507000 | 19 | 35 | 0.74 | 57 |

Table 1: Laboratory findings on admission.

Imaging studies

Chest X-ray did not reveal any abnormalities. So cervical and thoracic Computed tomography was (Figure 1) done and showed following findings:

- Multilobulated collection containing numerous pockets of air at neck, thoracic inlet and in the anterior chest wall invading the deepest aspect of the pectoralis major and minor muscles.
- Lesion extends within the right lung apex along the first and second ribs 9 cm in length.
- Infection extend within right anterior scalene muscle
- Dislocation of right sternoclavicular joint with anterior displacement of the clavicle.
- Irregular appearance of right clavicle, which suggests erosion due to infection or related to trauma.

CT scan findings were consistent with necrotizing skeletal muscle infection that necessitated urgent surgical intervention. Patient was started empirically on Ceftriaxone 600 mg intravenously twice a day and clindamycin 600 mg intravenously thrice daily.

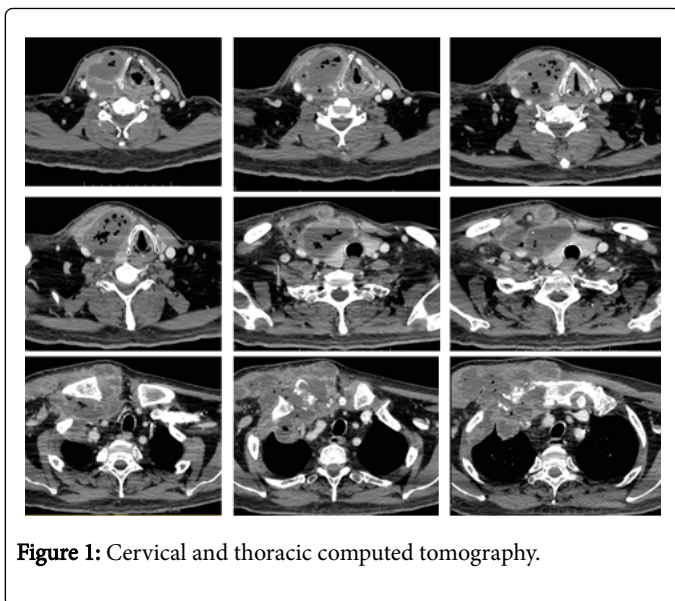


Figure 1: Cervical and thoracic computed tomography.

So urgently, patient was transferred to operation room, where he underwent thoracotomy with drainage of abscess and debridement of necrotic tissues. Two intraoperative cultures were taken from drained fluid. After 48 hours incubation at 37 degree on agar, colonies of *Aerococcus viridens* appeared. Both cultures grew exclusively *Aerococcus viridens*. No other microorganism appeared after 7 days of incubation.

Table 2 present the antibiogram of *A. viridens*.

| | | | |
|---|---|--------------|---|
| Penicillin | S | Kanamycin | I |
| Amoxicillin | S | Streptomycin | I |
| Erythromycin | S | Vancomycin | S |
| Tetracyclin | S | Teicoplanin | S |
| Levofloxacin | S | Linezolid | S |
| Moxifloxacin | S | Tigecycline | S |
| Gentamicin | I | Lincomycin | I |
| MIC (minimal inhibitory concentration): | | | |
| Penicillin G: 0.04 mg/dl | | | |
| Amoxicillin: 0.094 mg/dl | | | |

Table 2: Antibiogram of drained *A. viridens*.

Few days later patient started to have clinical and laboratory improvement and draining tubes were removed. Inflammatory markers also went down.

On day 12, patient was discharged on Moxifloxacin 400 mg PO daily for six weeks. No occurrence observed after one year of follow up.

Discussion

In this article, we present the first case of *Aerococcus viridians* induced pyomyositis. To our knowledge, there is not a single reported case of pyomyositis caused primarily by *A. viridans*.

In the described clinical case, the development of soft tissue infection was preceded by chest wall trauma 3 weeks prior to diagnosis, but not by surgical intervention. It is well known that in 20-50% of cases there is history of trauma to affected muscle [1-6]. Our patient sustained trauma to anterior chest where exist ribs and intercostals muscles.

Interestingly, the clinical symptoms were disproportion to radiological findings. There was discrepancy between the large-sized infected necrotized mass as shown by thoracic CT scan and the nonspecific clinical symptoms. The development of infection was not associated with clinical signs of intoxication and no documented fever upon presentation or during hospitalization stay. Numerous predisposing factors may play a role in the development of this silent infection such as immunodeficiency disorders [7-10] and diabetes mellitus [11].

The presenting symptoms of our patient were nonspecific, especially in the absence of intoxication signs. In our case, many diseases share same presenting symptoms and clinical signs. Differential diagnosis includes: Pyomyositis, necrotizing soft tissue infection, infected hematoma, deep neck space infection and osteomyelitis of the clavicle. Based on radiological findings, laboratory results and clinical picture, the most likely diagnosis was pyomyositis complicated with clavicle osteomyelitis.

Pyomyositis is defined as purulent infection of skeletal muscle that arises from hematogenous spread/or trauma and can be complicated with abscess formation [12]. Our patient has risk factors for pyomyositis including DM type II and trauma which is found in up to 50% of cases. *Staphylococcus aureus* is the most common cause of pyomyositis; it causes up to 90 percent of tropical cases and up to 75 percent of temperate cases [7,8,10,13,14]. In minority of cases pyomyositis has been reported to be caused by non-group A streptococci, pneumococci, and gram-negative enteric bacilli. Mycobacterial pyomyositis has also been reported [15-18]. Pyomyositis can also be polymicrobial, particularly in diabetic patients [10]. In the presented case, intraoperative drained pus sample grew only *A. viridens* which is an uncommon pathogen to cause pyomyositis. *Aerococcus* species have been identified in numerous reports as rare cause of infectious diseases including infective endocarditis, meningitis, arthritis and UTI, but not muscle infection [19-21].

Aerococci is generally saprophytic and have long been regarded to be uncommon in human infections. It was first described as a potential human pathogen in 1967 [22-24]. *Aerococcus* is a catalase negative gram positive coccus growing in small clusters. The genus contains following species: *A. christensenii*, *A. sanguinicola*, *A. suis*, *A. urinae*, *A. urinaequi*, *A. urinaehominis* and *A. viridans*. The clinical significance of these species has been clearly established for *A. urinae* and *A. viridans*. *A. urinae* is a rarely reported human pathogen that has been identified as responsible for urinary tract infections, septicemia, sepsis, endocarditis [25,26].

The microorganism isolated from our patient has grown in pure culture. The presence of pure culture indicated that the cultured germ is the cause of patient medical condition. Historically, *A. viridans* has been associated with different human infections such as endocarditis [27-29], urinary tract infections [30], arthritis [31], or meningitis [32]. There have been several cases of severe invasive aerococcal infections leading to mortality [33]. Moreover, these species are pathogens for crustaceans, causing gaffkemia in marine lobsters, and it has been associated with septicemia in sea turtles.

One may think that the presence of *Aerococcus viridens* in the culture medium, cannot prove that it is the direct cause of pyomyositis or osteomyelitis, as the findings in our particular patient does not fully satisfy the criteria Koch's postulates. However, clinical and laboratory improvement after antibiotic therapy covering *A. viridens* indicated that the cultured microorganism is in direct relation to the disease.

Aerococcus viridens is a rarely reported pathogen [34-36], possibly due to difficulties in the identification of the organism [37], and incidence of aerococcal infections has been underestimated because they are easily misidentified as streptococci or staphylococci, and thus, the introduction of matrix-assisted laser desorption ionization time-of-flight mass spectrometry (MALDI-TOF MS) carried great access to a rapid and accurate method [38,39]. MALDI/TOF is a diagnostic tool with much potential because it allows for the rapid identification of proteins and changes to proteins without the cost or computing power of sequencing nor the skill or time needed to solve a crystal structure in X-ray crystallography. So in the settings of high clinical suspicion of *Aerococcus* species infection and negative regular culture, further workup with MALDI-TOF MS should be considered.

Conclusion

In this case we presented the first case of *Aerococcus viridens* induced pyomyositis. *A. viridans* is unusual cause of soft tissue infection, but should be considered in the differential diagnosis when evaluating patients with suspected deep soft tissue infection. *A. viridens* infection is underestimated because of technical difficulties in the identification of this organism. The introduction of matrix-assisted laser desorption ionization time-of-flight mass spectrometry carried great success in accurate identification, as early identification of the offending organism guides physicians to appropriate treatment.

References

- Burkhart BG, Hamson KR (2003) Pyomyositis in a 69-year-old tennis player. Am J Orthop (Belle Mead NJ) 32: 562.
- Chusid MJ, Hill WC, Bevan JA, Sty JR (1998) Proteus pyomyositis of the piriformis muscle in a swimmer. Clin Infect Dis 26: 194.
- Jayoussi R, Bialik V, Eyal A, Shehadeh N, Etzioni A (1995) Pyomyositis caused by vigorous exercise in a boy. Acta Paediatr 84: 226.
- King RJ, Laugharne D, Kerslake RW, Holdsworth BJ (2003) Primary obturator pyomyositis: a diagnostic challenge. J Bone Joint Surg Br 85: 895.
- Koutures CG, Savoia M, Pedowitz RA (2000) Staphylococcus aureus thigh pyomyositis in a collegiate swimmer. Clin J Sport Med 10: 297.
- Meehan J, Grose C, Soper RT, Kimura K (1995) Pyomyositis in an adolescent female athlete. J Pediatr Surg 30: 127.
- Widrow CA, Kellie SM, Saltzman BR, Mathur-Wagh U (1991) Pyomyositis in patients with the human immunodeficiency virus: an unusual form of disseminated bacterial infection. Am J Med 91: 129.
- Schwartzman WA, Lambertus MW, Kennedy CA, Goetz MB (1991) Staphylococcal pyomyositis in patients infected by the human immunodeficiency virus. Am J Med 90: 595.
- Rodgers WB, Yodlowski ML, Mintzer CM (1993) Pyomyositis in patients who have the human immunodeficiency virus. Case report and review of the literature. J Bone Joint Surg Am 75: 588.
- Crum NF (2004) Bacterial pyomyositis in the United States. Am J Med 117: 420.
- Belsky DS, Teates CD, Hartman ML (1994) Case report: diabetes mellitus as a predisposing factor in the development of pyomyositis. Am J Med Sci 308: 251.
- Stevens DL, Bisno AL, Chambers HF, Dellinger EP, Goldstein EJ, et al. (2014) Practice guidelines for the diagnosis and management of skin and soft tissue infections: 2014 update by the infectious diseases society of America. Clin Infect Dis 59: 147.
- Chiedozi LC (1979) Pyomyositis. Review of 205 cases in 112 patients. Am J Surg. 137: 255.
- Gomez-Reino JJ, Aznar JJ, Pablos JL, Diaz-Gonzalez F, Laffon A (1994) Nontropical pyomyositis in adults, Semin Arthritis Rheum 23: 396.
- Lawn SD, Bicanic TA, Macallan DC (2004) Pyomyositis and cutaneous abscesses due to Mycobacterium avium: an immune reconstitution manifestation in a patient with AIDS. Clin Infect Dis 38: 461.
- Chu CK, Yang TL, Tan CT (2004) Tuberculous pyomyositis of the temporal muscle in a nonimmunocompromised woman: diagnosis by sonography. J Laryngol Otol 118: 59.
- Wang JY, Lee LN, Hsueh PR, Shih JY, Chang YL, et al. (2003) Tuberculous myositis: a rare but existing clinical entity. Rheumatology (Oxford) 42: 836.
- Ahmed J, Homans J (2002) Tuberculosis pyomyositis of the soleus muscle in a fifteen-year-old boy. Pediatr Infect Dis J 21: 1169.
- Janosek J, Eckert J, Hudac A (1980) Aerococcus viridans as a causative agent of infectious endocarditis. J Hyg Epidemiol Microbiol Immunol 24: 92-96.
- Taylor PW, Trueblood MC (1985) Septic arthritis due to Aerococcus viridans. J Rheumatol 12: 1004-1005.
- Untereker WJ, Hanna BA (1976) Endocarditis and osteomyelitis caused by Aerococcus viridans. Mt Sinai J Med 43: 248-252.
- Williams RE, Hirsch A, Cowan ST (1953) Aerococcus, a new bacterial genus. J Gen Microbiol 8: 475-480.
- Clausen OG (1964) The discovery, isolation, and classification of various alpha-hemolytic micrococci which resemble aerococci. J Gen Microbiol 35: 1-8.
- Coster E, White HR (1964) Further studies on the genus Pediococcus. J Gen Microbiol 37: 15-31.
- Christensen JJ, Jensen IP, Faerk J, Kristensen B, Skov R, et al. (1995) Bacteremia/septicemia due to Aerococcus-like organisms: report of seventeen cases. Danish ALO Study Group. Clin Infect Dis 21: 943-947.
- Senneby E, Petersson AC, Rasmussen M (2012) Clinical and microbiological features of bacteraemia with Aerococcus urinae. Clin Microbiol Infect 18: 546-550.
- Parker MT, Ball LC (1976) Streptococci and aerococci associated with systemic infection in man. J Med Microbiol 9: 275-302.
- Rasmussen M (2012) Aerococci and aerococcal infections. J Infect 6: 467-474.
- Rasmussen M (2011) Aerococci: hard to find and classify. Rev Argent Microbiol 43: 312.
- Leite A, Vinhas-Da-Silva A, Felício L, Vilarinho AC, Ferreira G (2010) Aerococcus viridans urinary tract infection in a pediatric patient with secondary pseudohypoadosteronism. Rev Argent Microbiol 42: 269-270.
- Nasoodi A, Ali AG, Gray WJ, Hedderwick SA (2008) Spondylodiscitis due to Aerococcus viridans. J Med Microbiol 57: 532-533.
- Nathavitharana KA, Arseculeratne SN, Aponso HA, Vijeratnam R, Jayasena L, et al. (1983) Acute meningitis in early childhood caused by Aerococcus viridans. Br Med J (Clin Res Ed) 286: 1248.
- De Jong MFC, Soetekouw R, ten Kate RW, Veenendaal D (2010) Aerococcus urinae: severe and fatal bloodstream infections and endocarditis. J Clin Microbiol 48: 3445-3447.
- Williams RE, Hirsch A, Cowan ST (1953) Aerococcus, a new bacterial genus. J Gen Microbiol 8: 475-480.
- Rasmussen M (2015) Aerococcus: an increasingly acknowledged human pathogen. Clin Microbiol Infect 22: 22-27.
- Yasukawa K, Afzal Z, Mbang P, Stager CE, Musher DM (2014) Aerococcal infection at three US Tertiary Care Hospitals. South Med J 107: 642-647.
- Cattoir V, Kobal A, Legrand P (2010) Aerococcus urinae and Aerococcus sanguinicola, two frequently misidentified uropathogens. Scand J Infect Dis 42: 775-780.

-
38. Senneby E, Nilson B, Petersson AC, Rasmussen M (2013) Matrix-assisted laser desorption ionization-time of flight mass spectrometry is a sensitive and specific method for identification of aerococci. *J Clin Microbiol* 51: 1303–1304.
39. Christensen JJ, Dargis R, Hammer M, Justesen US, Nielsen XC, et al. (2012) Matrix-assisted laser desorption ionization-time of flight mass spectrometry analysis of Gram-positive, catalasenegative cocci not belonging to the *Streptococcus* or *Enterococcus* genus and benefits of database extension. *J Clin Microbiol* 50: 1787–1791.