

Transcatheter Cerebral Revascularization in the Treatment of Atherosclerotic Lesions of the Brain

Ivan V Maksimovich*

Department of Interventional Neuroangiology, Clinic of Cardiovascular Diseases Named after Most Holy John Tobolsky, Moscow, Russia

Abstract

Background: The research investigates cerebral blood supply recovery by means of transcatheter laser revascularization in patients with advanced brain atherosclerosis.

Materials and Methods: 974 patients aged 29-81 (mean age 74) with various types of cerebral atherosclerosis. Transcatheter treatment was performed in 594 (60.99%) cases-Test Group. Conservative treatment was performed in 380 (39.01%) cases-Control Group. Examination plan: CDR, MMSE, IB evaluation, cerebral SG, REG, CT, MRI, MRA, MUGA. High-energy lasers were used for main intracranial arteries revascularization; low-energy lasers-for intracranial distal branches revascularization.

Results: Treatment results were studied in the early period (2-6 months) and in 2-10 years. Test Group: 478 (80.47%) patients showed good clinical outcome, 234 (48.95%) of them were re-examined: results persisted in 217 (92.73%), satisfactory outcome was observed in 17 (7.27%). Satisfactory clinical outcome-96 (16.16%) patients, 55 (57.29%) re-examined: results persisted in 50 (90.91%), relatively satisfactory outcome-in 5 (9.09%). Relatively satisfactory clinical outcome-20 (3.37%), re-examined 10 (50.00%): results persisted in 8 (80.00%), relatively positive outcome-2 (20.00%). Control Group: good clinical outcome was not obtained. Satisfactory clinical outcome was obtained in 65 (17.11%), 37 (56.92%) were re-examined: results persisted in 14 (37.84%), relatively satisfactory outcome-in 23 (62.15%). Relatively satisfactory clinical outcome was obtained in 122 (32.11%), re-examined 75 (61.48%): results persisted in 34 (45.33%), relatively positive outcome-in 41 (54.67%). Relatively positive outcome was obtained in 193 (50.78%), re-examined 86 (44.56%): results persisted in 40 (46.51%), worsened condition was detected in 46 (53.49%).

Conclusions: The method of transcatheter laser revascularization of cerebral vessels is physiological, effective and of small traumatism; it stimulates natural angiogenesis, collateral, capillary revascularization and mental and motor disorders regression. The effect persists up to 10 years, which makes the method significantly different from conservative treatment.

Keywords: Cerebrovascular disease; Ischemic stroke; Transcatheter laser revascularization; Cerebrovascular insufficiency; Regeneration

Introduction

The most common cause of ischemic brain lesions is atherosclerosis. Due to atherosclerotic narrowing of cerebral vessels, circulatory disorders develop causing motor and cognitive disorders, subsequent strokes and deaths [1-3]. In the US alone, 800 thousand people die from stroke each year [4]. The brain comes first in the human body as far as blood supply is concerned, and therefore it is extremely sensitive to malnutrition-as no other part is [5]. Intracranial arterial and capillary bed are of great importance in cerebral blood supply [2,6]. One cubic centimeter of brain tissue contains about 3-4 thousand capillaries [5].

With the development of ischemia circulation changes, angiogenesis is stimulated, collateral vessels develop and blood is indirectly taken to ischemic areas [2,6,7]. In this process, an important part is played by the time during which the alteration of circulation occurs [4,8]. For many years, it has been thought that atherosclerotic lesions of major extracranial vessels perform the main role in the development of cerebral ischemia [6,9]. The importance of the main vascular branches is naturally very significant, but their main function is to transport blood to the brain. Slowly developing occlusions of two or even three extracranial vessels often occur without obvious symptoms and do not lead to the development of massive stroke [2,7].

Atherosclerosis is a systemic disease, and is practically always widespread affecting many arterial branches including small ones [4-7]. This process causes the development of long-term chronic ischemia leading to slowly growing neurodegenerative and atrophic changes

in the cerebral tissue, while it may not be accompanied by ischemic attacks and visualized strokes [2,6,7]. If that is the case, it is fairly difficult to identify multiple micro strokes during CT and MRI, due to the small size of the ischemic areas bordering the resolution of the equipment used [7]. Larger ischemic strokes develop in a longer-term period during future progression of atherosclerosis, they may merge and are generally a consequence of untimely treatment [2,7]. The development of cerebrovascular insufficiency and ischemia is naturally caused by hyperlipidemia, hypertension, diabetes, disorders of systemic hemodynamics, microemboli, but these reasons are secondary to the background of established atherosclerotic process [10,11].

Classic conservative treatment of cerebrovascular insufficiency can be effective only in the early stages of the disease, when there are no occlusive lesions, and vascular stenosis is not pronounced. At later stages, transcatheter or reconstructive surgery is required [12]. There have recently appeared studies dedicated to successful use

*Corresponding author: Ivan V Maksimovich Department of Interventional Neuroangiology, Clinic of Cardiovascular Diseases Named after Most Holy John Tobolsky, Moscow, Russia, Tel: +74954390945; E-mail: carvasc@yandex.ru

Received January 25, 2016; Accepted February 23, 2016; Published February 26, 2016

Citation: Maksimovich IV (2016) Transcatheter Cerebral Revascularization in the Treatment of Atherosclerotic Lesions of the Brain. Brain Disord Ther 5: 209. doi:10.4172/2168-975X.1000209

Copyright: © 2016 Maksimovich IV. This is an open-access article distributed under the terms of the Creative Commons Attribution License, which permits unrestricted use, distribution, and reproduction in any medium, provided the original author and source are credited.

of transcranial laser radiation in the treatment of the consequences of ischemic stroke [13,14], cranial trauma and dementia [15-17]. These studies indicate a good neuroprotective effect of the treatment contributing to successful neurorehabilitation, but it should be noted that these treatments are also effective in the early, not severe stages of the disease. Reconstructive surgery is well-proven as far as extracranial vessels are concerned [18,19]. Due to the anatomical features and small diameter of the vessels, carrying out of similar operations on intracranial arterial bed is quite difficult. Implementation of extra-intracranial arterial anastomosis is not always effective, and lately there have been disputes concerning the feasibility of such operations [20]. Transcatheter therapies, such as balloon angioplasty and stenting of various kinds, have proved well on extracranial brachiocephalic branches [21,22]. Such interventions on intracranial arteries are often performed in the acute period and are fulfilled within the proximal part of the channel [23,24]. Distal intracranial vascular branches, being of a small diameter, present certain difficulties in carrying out these procedures [25].

Consequently, there remains a need to develop new integrated transcatheter methods of treatment of atherosclerotic lesions of the brain. The present study investigates the possibility of recovery of cerebral arterial channel in patients with advanced atherosclerosis of the brain by means of transcatheter laser revascularization method, and evaluation of mental disorders reduction and cognitive and motor functions recovery of these patients in the near and long-term period after the treatment.

Materials and Methods

All the studies and all transcatheter interventions have been carried out with the approval of the Ethics Committee, as well as with the consent of the examined and treated patients and their relatives.

We examined 974 patients aged from 29 to 81 (average age 74) suffering from various types of atherosclerotic lesions of cerebral vessels, of whom 722 were male (74.13%) and 252-female (25.87%) patients.

The examination plan included assessment of the severity of dementia (CDR), assessment of cognitive impairment (MMSE), evaluation of the activities of daily living (IB), cerebral scintigraphy (SG), rheoencephalography (REG), cerebral computed tomography (CT), cerebral magnetic resonance imaging (MRI), cerebral magnetic resonance angiography (MRA), cerebral multi-gated angiography (MUGA).

Determination of the severity of dementia was made according to J.C. Morris's Clinical Dementia Rating scale (CDR) [26]. Primary examination was conducted either at the patient's first visit or on the admission day, secondary -before the patient's discharge and then at intervals of 6-12 months.

Assessment of cognitive impairment was conducted by means of mini-mental state examination (MMSE) [27]. Primary examination was conducted either at the patient's first visit or on the admission day, secondary-before the patient's discharge and then at intervals of 6-12 months.

Evaluation of the activities of daily living was carried out with Index Bartels Functional Evaluation: The Barthel Index (IB) [28]. Primary examination was conducted at the patient's admission, secondary-before the patient's discharge and then at intervals of 6-12 months.

SG of the brain, with the determination of cerebral blood flow velocity, was carried out on a gamma camera (Ohio Nuclear, U.S.)

following the classical method in dynamic and static mode with TC 99M pertechnetate 555. Primary examination was conducted at the patient's admission and then at intervals of 6-12 months.

REG was conducted by means of "Reospektr-8" (Neurosoft, Russia) in accordance with the standard automated method with the identification of pulse blood flow in the cerebral hemispheres. Primary examination was conducted at the patient's admission, secondary-before the patient's discharge and then at intervals of 6-12 months.

CT and MRI of the brain were performed on "Somatom" (Siemens), "Hi Speed" (GE), "Tomoscan" (Philips), "Apetro Eterna" (Hitachi) following the classical method. Primary examination was conducted at the patient's admission and then at intervals of 6-12 months.

MRA of the brain were performed on "Apetro Eterna" (Hitachi) following the classical method in the long-term period after the treatment.

MUGA of the brain was performed on apparatus «Advantx» (GE) following the classical method of transfemoral access. Synchronously, taking into account the start and rate of administration, 10-12 ml of Omnipack 350 was introduced intra-carotidally and 7-8 ml intra-vertebrally. The registration was carried out in direct and side projections in constant subtraction mode at a speed of 25 frames per second. Further on, frame by frame analysis of the angiograms received in each phase contrast was conducted [29]. Capillary density contrast analysis was performed at the corresponding phase by means of an automatic method using computer program "Angio Vision" based on the determination of the degree of blackening of the corresponding part of the image [30,31].

Criteria for selection of patients for this research:

- 1) consent of the patient and her/his relatives to conduct the examination and treatment;
- 2) somatic condition of patients that allowed to carry out the examination and treatment;
- 3) signs of chronic cerebrovascular insufficiency;

According to ischemic lesion type, the patients were divided:

- Transient ischemic attacks and minor inulty-268 (27.52%) patients;
- Cerebrovascular chronic insufficiency-706 (72.48%).

The patients' examination revealed the following disorders:

- Signs of dementia equal to CDR-1 were detected in 271 (27.82%) cases;
- Signs of cognitive impairment (MMSE score below 28 points) were detected in 244 (25.05%) cases;
- Signs of reduction of the activities of daily living (IB below 100 points) were detected in 42 (4.31%) cases.
- General involutive changes of the cerebral cortex accompanied by subarachnoid space extension were detected in 780 (80.08%) cases;
- Expansion of Sylvian fissure was found in 632 (64.89%) cases;
- Reduction of the clearness of gray and white matter borders was found in 475 (48.77%) cases;

- Signs of unocclusive hydrocephalus were detected in 417 (42.81%) cases;
- Signs of leucoaraiosis were detected in 162 (16.63%) cases;
- Micro-focal (up to 2-3 cm) postischemic brain cysts were detected in 148 (15.20%) cases;
- Single and multiple microcysts (up to 2-5 mm) were detected in 126 (12.94%) cases;
- Absence of postischemic cysts against the background of atherosclerotic lesions was detected in 700 (71.87%) cases (one cannot exclude the possibility of these patients having very small cysts-smaller than the resolution of the equipment used);
- Reduced blood flow in the cerebral hemispheres was observed in all 974 (100%) cases;
- Reduced pulsed volume blood flow in the carotid and vertebrobasilar systems was detected in all 974 (100%) cases;
- Calcium deposits on the walls of cerebral blood vessels were detected in 799 (82.03%) cases;
- Multiple atherosclerotic stenotic or occlusive lesions in the basin of the front, middle or posterior cerebral arteries were detected in all 974 (100%) cases. Of these, two-sided lesion was detected in 918 (94.25%) cases;

Transcatheter treatment was undergone by 594 (60.99%) patients aged from 29 to 80 (average age 74), of whom 432 (72.72%) were male and 162 (27.27%)-female patients-Test Group.

Conservative treatment was undergone by 380 (39.01%) patients aged from 33 to 81 (average age 75), of whom 260 (68.42%) were male and 120 (31.58%)-female patients-Control Group.

Clinical outcomes were studied in the early stages after the treatment of 2-6 months and again in the long term of 2-10 years. In the long-term, 497 (51.03%) patients were re-examined. Of these patients, Test Group amounted to 299 (60.16%) patients, Control Group-to 198 (39.84%) patients.

Test group

For revascularization of the brain, we used the method of transcatheter laser revascularization [2,7,29,30], which allows working on a fairly tortuous vessels of different diameters. The efficacy and safety of this method has been proved in prior experimental and clinical studies [2,7,25,32-35]. The essence of the method is as follows:

High-energy impulse laser systems were used to conduct the revascularization of the brain with major intracranial arteries lesions; low-energy continuous laser systems were used for the revascularization of the brain with distal intracranial branches lesions [7, 29-31].

The essence of the method is the following: Under local anesthesia, according to Seldinger's classical method, the common femoral artery is punctured and catheterized with an installation of an introducer with a diameter of 6-9F. Through this introducer and through coaxially brought guiding catheters installed in the general and further on in the internal carotid or in the vertebral artery, is brought a flexible fiber-optic instrument with a diameter of 50 to 200 micrometers, coupled with the laser unit. The fiber-optic instrument is guided to the site of intracerebral arteries lesion, after which the laser treatment is carried out. The distal end of the fiber-optic instrument is constantly washed

with heparinized saline solution. Given the specificity of laser exposure on atherosclerotic tissue and the vascular wall [29,30], the use of distal protection is not required. To carry out X-ray control, small doses of radiopaque substance are periodically introduced. The exposure time depends on the nature of the atherosclerotic lesion, the type of the laser system used, and is in general from 30 seconds to 40 minutes. After the endovascular intervention the patient undergoes repeated cerebral multi-gated angiography following the procedure described above, the results of which determine the degree of revascularization and restoration of the cerebral vascular bed [2,35]. We assume that if the cerebral blood flow has not been fully restored during the first attempt of the intervention, the manipulation can be repeated, but it was not necessary during the transcatheter interventions described.

Taking into consideration the MUGA data and the fact that atherosclerosis is a systemic disease and cerebral vascular lesions progress in various basins, not just in the particular part of the bed, transcatheter interventions were usually carried out from two sides, in order to improve the blood supply of the whole brain. It allows for not only direct revascularization, but it also gives an opportunity to improve blood flow through the collateral bed from contralateral vascular basin [35].

The transcatheter treatment was followed by supportive therapy carried out by common interventional neuroangiology schemes and dosing. The patients underwent conventional desagrigant, anticoagulant, vasodilator and nootropic therapy including Aspirin, Heparin, indirect anticoagulants (depending on the blood coagulation indicators), Pentoxifylline 100 mg, Complamin 150 mg, Inosin 200 mg, Nootropil (Piracetam) 1200 mg (or Gliatilin 1000 mg) intravenously, with a drop counter, №10-15, and then they took pills. Further on, supportive therapy courses were repeated twice a year.

Control group

All patients also received desagregant, anticoagulant, vasodilator and nootropic therapy including Aspirin, Heparin, indirect anticoagulants (depending on the indicators of blood coagulation), Pentoxifylline 100 mg, Complamin 150 mg, Inosin 200 mg, Nootropil (Piracetam) 1200 mg (or Gliatilin 1000 mg) intravenously, dropwise, № 10-15, with subsequent transfer to pills. Then the treatment was repeated twice a year.

Long-term re-examination of both groups included:

- CDR, MMSE, IB assessment (all patients);
- Cerebral CT, MRI, scintigraphy (SG), rheoencephalography (REG) (all patients);
- Cerebral MRA 78 (26.09%) Test Group patients and 43 (21.72%) Control Group patients;
- Cerebral MUGA 66 (22.07%) Test Group patients and 24 (12.12%) Control Group patients.

Results

The results obtained were divided into the following groups:

- Good clinical outcome after the treatment was considered to be almost complete restoration of mental and motor functions and activities of daily living.
- Satisfactory clinical outcome was considered to be incomplete restoration of mental and motor functions and activities of daily living.

- Relatively satisfactory clinical outcome was considered to be a partial recovery of mental and motor functions and activities of daily living.
- Relatively positive clinical outcome was considered to be the absence of negative dynamics with a slight reduction of mental and motor functions and activities of daily living.

Test group

A good immediate angiographic outcome manifested in the restoration of the lumen and patency of the vessels, as well as in collateral revascularization on the side with more pronounced atherosclerosis, was obtained in 571 (96.13%) cases. Besides, improved blood supply in the cerebral hemispheres by means of the collateral revascularization from contralateral vascular basins was obtained in 570 (95.95%) cases. In the short-term period, according to SG data, improved blood flow in the cerebral hemispheres, both on the more affected and on the contralateral side, was observed in all 594 (100%) cases, and the positive trend remained during the whole observation period.

In the short-term period, according to REG data, improved pulse-volume blood flow in the carotid and vertebrobasilar basins on the affected and contralateral sides was found in all 594 (100%) cases, and the positive trend remained during the whole observation period.

According to CT and MRI in the first 6-24 months after the transcatheter treatment, the patients tended to have diminishing general involutive changes of the cerebral cortex accompanied by narrowing of subarachnoid space:

- General involutive changes in the cerebral cortex decreased in 453 (95.17%) of 476 cases;
- Reduction of Sylvian fissure narrowing was observed in 365 (94.56%) of 386 cases;
- Tendency to restore clearness of boundaries between gray and white matter of the brain was diagnosed in 192 (66.44%) of 289 cases;
- Reduction of signs of unocclusive hydrocephalus was detected in 165 (64.96%) of 254 cases;
- Signs of leucoaraiosis were detected in 92 (92.93%) of 99 cases;
- Signs of residual effects of micro-focal postischemic brain cysts were detected in 12 (13.33%) of 90 cases;

- Single or multiple microcysts were not identified in any case.
- Repeated cerebral MUGA or MRA were performed at intervals of 2-10 years after the treatment in 141 (23.74%) patients:
- Preserved lumen and patency of the vessels, as well as enhanced collateral revascularization, were obtained in 134 (95.04%) cases;
 - Preserved improved cerebral perfusion due to collateral revascularization from the contralateral basin was obtained in 132 (93.62%) cases.

Clinical results

- In the early period, good clinical outcome was achieved in 478 (80.47%) patients, of whom 234 (48.95%) were re-examined in the long-term period; the result was retained in 217 (92.73%), satisfactory outcome was observed in 17 (7.27%).
- In the early period, satisfactory clinical outcome was obtained in 96 (16.16%) cases, of whom 55 (57.29%) patients were re-examined in the long-term period; the result was retained in 50 (90.91%), relatively satisfactory outcome was detected in 5 (9.09%) cases.
- In the early period, relatively satisfactory clinical outcome was achieved in 20 (3.37%) cases, 10 (50.00%) patients were re-examined in the long-term period; the result was retained in 8 (80.00%), relatively positive outcome was detected in 2 (20.00%).

Statistical analysis is presented in Table 1.

Treatment Examples

Patient H., 60 years old, female, suffered a small ischemic stroke in the right hemisphere resulting in partial left-sided hemiparesis; the patient notes decreased memory and vestibular disorders. In 2 months after the stroke, there are no signs of dementia, cognitive impairment level is equal to 26 MMSE points, the level of everyday life-to 90 IB points. CT of the brain revealed a moderate expansion of the subarachnoid space and a small heterogeneous post-ischemic cyst in the right hemisphere (Figure 1).

SG and REG showed quite a marked reduction in blood flow and pulse volume with the predominance of the process to the right.

Category	Aggregate Results Frequency Table: Short-Term Period					Aggregate Results Frequency Table: Long-Term Period			
	Group	Count	Cumulative Count	Percent	Cumulative Percent	Count	Cumulative Count	Percent	Cumulative Percent
Good Clinical Outcome	Test	478	478	80.47138	80.4714	217	217	71.38158	71.3816
Satisfactory Clinical Outcome	Test	96	574	16.16162	96.6330	67	284	22.03947	93.4211
Relatively Satisfactory Clinical Outcome	Test	20	594	3.36700	100.0000	13	297	5.92105	99.3421
Relatively Positive Clinical Outcome	Test	-	-	-	-	2	299	0.65789	100.0000
Satisfactory Clinical Outcome	Control	65	65	17.10526	17.1053	14	14	7.07071	7.0707
Relatively Satisfactory Clinical Outcome	Control	122	187	32.10526	49.2105	57	71	28.78788	35.8586
Relatively Positive Clinical Outcome	Control	193	380	50.78947	100.0000	127	198	64.14141	100.0000

The analysis of the results of the early and late periods of treatment within each group by means of the Sign test revealed significant differences ($p < 0.01$) between the initial treatment period and the results of the treatment at a later stage in each group. To compare test and control groups at early and late stages of therapy, an analysis of contingency tables was conducted using the chi-square test. The compared groups differed significantly in the level of clinical effect at each stage of therapy ($p < 0.01$), and test group results were significantly better than control group results.

Table 1: Comparative characteristics of clinical results obtained after treatment of test and control group patients.

Cerebral MUGA revealed multiple occlusions of the distal branches of the right middle cerebral artery, multiple diffuse stenosis of intracranial branches (Figure 2).

The patient underwent transcatheter laser revascularization first of the right and then of the left hemisphere. Postoperative cerebral MUGA revealed completely restored patency and lumen of the distal branches of the right middle cerebral artery and pronounced collateral revascularization on the two sides (Figure 3).

Repeated SG and REG showed positive dynamics of blood flow and pulse volume in both hemispheres of the brain.

A month later, the patient demonstrated the restoration of motor functions, intellectual abilities and professional skills. MMSE-30 points, IB-100 points; the patient returned to her professional activity.

In 12 months, repeated CT of the brain revealed restoration of subarachnoid space, reduction in the size of the post-ischemic cyst with signs of cerebral tissue structure recovery (Figure 4).

6 years after the transcatheter treatment, the patient does not have any complaints, there are no signs of dementia, no cognitive impairment,

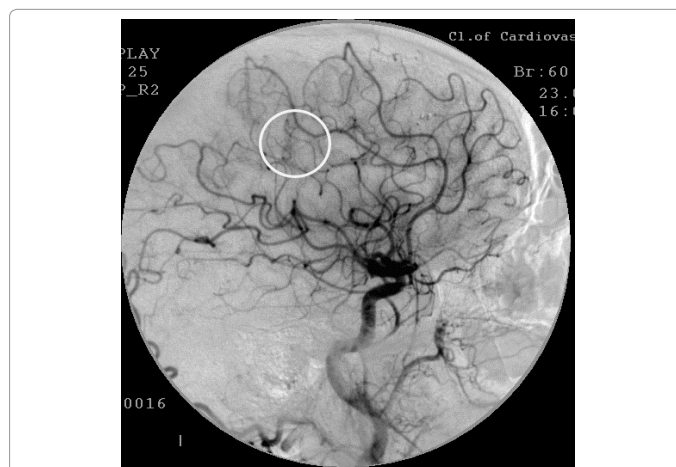


Figure 3: Same patient H.: Right-sided carotid MUGA (lateral projection). After the intervention: restoration of the lumen and permeability of distal branches of the right middle cerebral artery, improvement of collateral blood flow.

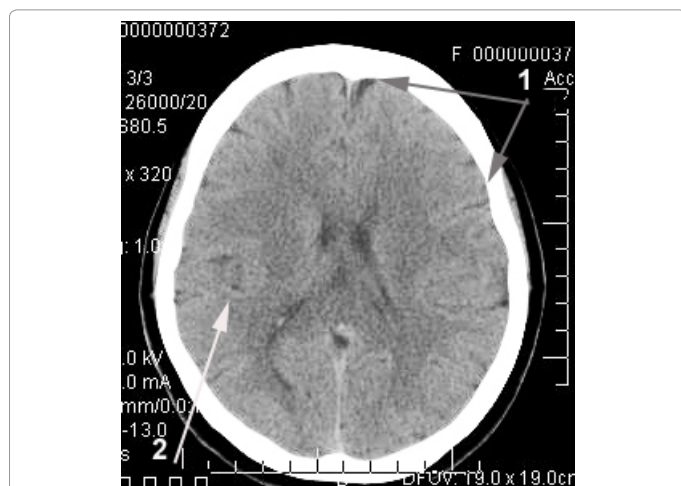


Figure 1: Patient H.: Female, 60 years old: CT of the brain. Before the Intervention: 1) moderate expansion of the subarachnoid space; 2) moderate heterogeneous post-ischemic cyst in the right middle cerebral artery region.

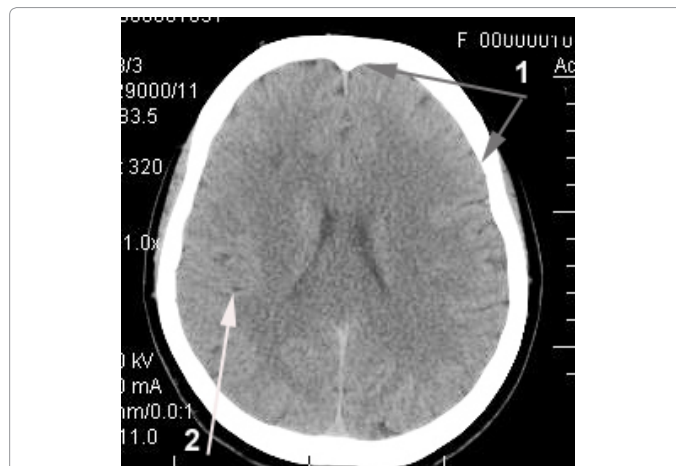


Figure 4: Same patient H.: CT of the brain. 12 Months after the Intervention: 1) subarachnoid space restoration, 2) reduction in the size of the post-ischemic cyst with signs of cerebral tissue structure recovery.

and she is actively engaged in intellectual activity, IB-100. CT of the brain revealed no signs of residual effects of the post-ischemic cyst; cerebral tissue structure of the right hemisphere is restored (Figure 5).

Cerebral MRA (Figure 6) showed the patency and lumen of the distal branches of the right internal carotid artery are completely preserved; there is further progression of collateral revascularization.

Control Group

Immediately after the course of conservative treatment, the patients had no negative dynamics, and there was certain positive dynamics manifested in diminishing mental and motor disorders.

In the short-term period, SG and REG showed partial improvement of blood flow and pulse volume in the cerebral hemispheres in 254 (66.84%) patients. The improvement was not stable, and subsequent examination after 12 months reported partial regression in 129 (50.78%) cases.

CT and MRI in the first 6-24 months after the treatment showed no substantial reduction of the involutive changes in the brain tissue in any of 380 patients. In the longer-term period, 198 (52.11%) patients

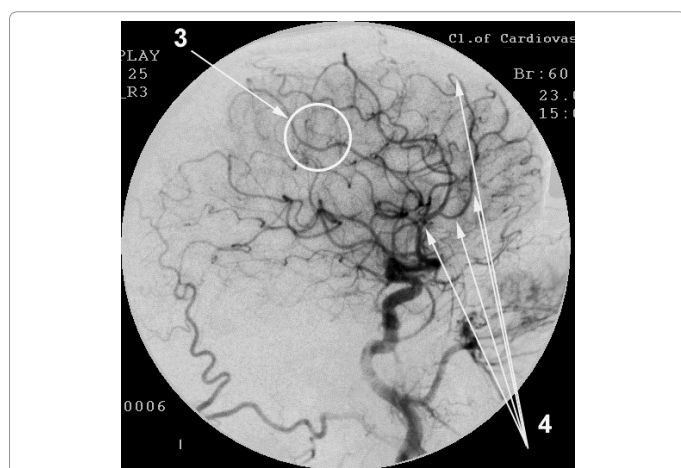


Figure 2: Same patient H.: Right-sided carotid MUGA (lateral projection). Before the intervention: 3) occlusion of distal branches of the right middle cerebral artery; 4) multiple stenosis of intracranial branches.

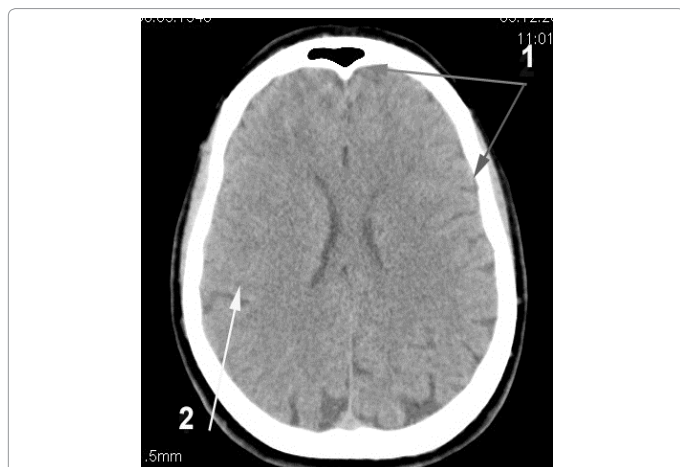


Figure 5: Same patient H.: CT of the brain. 6 Years after the Intervention: 1) the structure of the right hemisphere cerebral tissue is restored. 2) no signs of residual effects of the post-ischemic cyst.

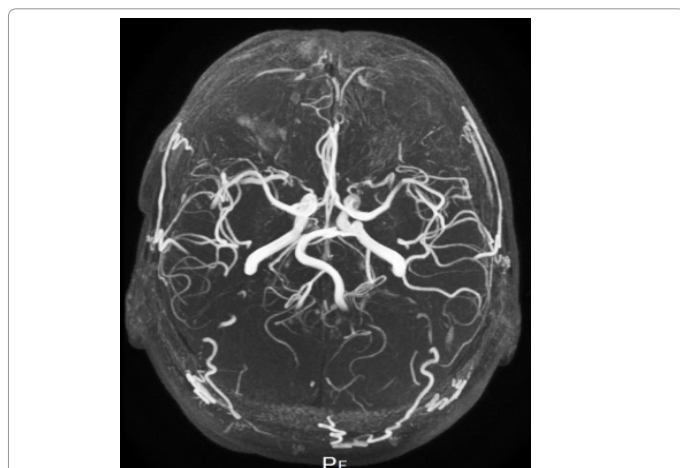


Figure 6: Same patient H.: MRA of the brain. 6 Years after the Intervention: the patency and lumen of the distal branches of the right internal carotid artery are completely preserved, there is further progression of collateral revascularization.

showed growing involutive changes.

Repeated cerebral MUGA or MRA were performed in 67 (17.63%) cases at intervals of 2-10 years after the treatment started. There were no significant changes in the angioarchitectonics; 62 (92.54%) patients had further progression of the atherosclerotic process.

Clinical results

- Good clinical outcome was not received;
- In the early period, satisfactory clinical outcome was achieved in 65 (17.11%) patients, of whom 37 (56.92%) patients were re-examined in the long-term period; the result was retained in 14 (37.84%), relatively satisfactory outcome was detected in 23 (62.15%);
- In the early period, relatively satisfactory clinical outcome was achieved in 122 (32.11%) patients, of whom 75 (61.48%) patients were re-examined in the long-term period; the result was retained in 34 (45.33%), relatively positive outcome was detected in 41 (54.67%);

- In the early period, relatively positive outcome was achieved in 193 (50.78%) patients, of whom 86 (44.56%) were re-examined in the long-term period; the result was retained in 40 (46.51%), deterioration was detected in 46 (53.49%).

Discussion

The widespread conservative treatment applied for atherosclerotic lesions of the brain is simple; it does not require complex and expensive examination methods or significant investment. Unfortunately, it is only effective in the early stages of the disease as it cannot significantly improve blood supply [2,7]. The effect obtained does not often lead to the desired neurorehabilitation and marked recovery of cognitive and motor functions of the patient, and it is often not lasting in nature [12]. In this study, it is confirmed by the results of treatment of control group patients. There is not a single case of good clinical outcome, and in the long-term period most of the treated patients experienced regression.

Cerebral arteriosclerosis is widespread and of a bilateral nature, which makes intervention difficult to perform [22,25]. To carry out any interventions, it is necessary to clearly define the localization of atherosclerotic lesions and to always examine both extracranial and intracranial vessels [7]. Cerebral angioarchitectonics and hemodynamics have their own characteristics. In the case of a more widespread atherosclerotic lesion in one hemisphere, it is necessary to assess the condition of cerebral vessels in the other hemisphere as well. It is also necessary to evaluate the presence of cross-flows between the hemispheres. Conducting operational activities on only one, even the more affected side is often not inexpedient [2,9]. The small diameter and complex anatomical location hinders intervention on intracranial vascular pool [21,22,24]. It gives a number of restrictions for the use of common treatment methods. Conducting reconstructive surgery is extremely difficult [18,19]. Conducting traditional transcatheter interventions requires the use of stents of an extremely small diameter [24,25]. The application of these stents contributes to the development of early thrombosis.

Nowadays, to achieve the recovery of the patency of intracranial arterial branches, as well as to stimulate angiogenesis, the work of collaterals, and to improve capillary blood flow, one can only turn to transcatheter methods using laser energy and light-guiding instruments of very small diameters which is an advantage of this method and which illustrates its prospects [2,7,30].

Taking into account MUGA data, during laser revascularization of the brain, we practically always carried out interventions on both sides. Improved blood circulation in the hemisphere that is more affected by atherosclerosis contributes to its functional recovery [30]. Improvement of blood supply in the other, less affected contralateral hemisphere, also contributes to the improvement of its functionality and at the same time, by stimulating collateral blood supply, improves blood flow in the opposite hemisphere [2,7,29]. Bilateral improvement of blood circulation leads to overall brain functional recovery and promotes more rapid and marked neurorehabilitation [7,31].

Targeted high-energy laser treatment allows destroying atherosclerotic tissue and restoring patency and lumen of atherosclerotic vessels without causing adverse effects on the vascular wall [7,29]. Appearing atherosclerotic tissue decomposition products have an extremely small size of 2-6 micrometers [30,35], they are utilized in a natural way that does not require the use of distal protection [2,35].

The mechanism of low-energy laser effect is in the powerful stimulation of natural physiological angiogenesis [2,34,35] causing

collateral and capillary tissue revascularization [35-38]. At the same time, laser energy deeply penetrates into cerebral tissue, stimulates metabolism in neurons increasing their energy resource due to the impact on mitochondrial apparatus in the cells and thereby producing additional neuroprotective effects [7,35,38].

Many authors who conducted both experimental and clinical studies on extracranial laser effects on the brain [13-17,39-42] confirm neuroprotective effect of laser energy.

Subsequent post-treatment recovery of cerebral tissue structure and gradual increase of its mass indicate developing regenerative processes [7,35,39,41]. Other authors [43] have confirmed the possibility of regenerative processes in the cerebral tissue.

Conclusions

The method of transcatheter laser revascularization of cerebral vessels can restore patency and lumen of vessels of different diameter; it simultaneously stimulates natural angiogenesis, causes collateral and capillary revascularization both in the ischemic region and in closely located tissue, and promotes reparative processes in the cerebral tissue and subsequent neurorehabilitation.

The method is physiological, effective and of small traumatism for patients suffering from cerebral arteriosclerosis and chronic cerebrovascular insufficiency.

The effect obtained after conducted transcatheter treatment lasts for a long time (up to 10 years and more) causing regression of mental and motor impairment that can improve the quality of life of patients. It makes the proposed method significantly different from that of conservative treatment.

Conflict of Interest

The authors declare no conflict of interest.

References

- Gillum RF, Kwagyan J, Obisesan TO (2011) Ethnic and geographic variation in stroke mortality trends. *Stroke* 42: 3294-3296.
- Maksimovich IV (2012) Transcatheter Treatment of Atherosclerotic Lesions of the Brain Complicated by Vascular Dementia Development. *World Journal of Neuroscience* 2: 200-209.
- Frölich AM, Psychogios NM, Klotz E, Knauth M, Knauth M, et al. (2012) Angiographic Reconstructions From Whole-Brain Perfusion CT for the Detection of Large Vessel Occlusion in Acute Stroke. *Stroke* 43: 97-102.
- Abou-Chebl A (2013) Management of acute ischemic stroke. *Curr Cardiol Rep* 15: 348.
- Gjulev NM, Pustozertsev VG, Gjulev SN (2002) *Cerebrovascular Diseases*. BINOM, Moscow.
- Qureshi AI, Caplan LR (2014) Intracranial atherosclerosis. *Lancet*. 15 383 (9921): 984-998.
- Maksimovich IV (2013) Possibilities of transcatheter treatment of patients after extensive ischemic stroke. *World Journal of Neuroscience* 3: 171-185.
- Pendlebury ST, Wadling S, Silver LE, Mehta Z, Rothwell PM (2011) Transient cognitive impairment in TIA and minor stroke. *Stroke* 42: 3116-3121.
- Caplan LR, Thomas AJ, Inoa V (2014) Interventional treatment of brain ischemia related to intracranial cerebrovascular occlusive lesions. *Curr Opin Neurol* 27: 1-7.
- ElAli A, Doeppner TR, Zechariah A, Hermann DM (2011) Increased Blood-Brain Barrier Permeability and Brain Edema After Focal Cerebral Ischemia Induced by Hyperlipidemia: Role of Lipid Peroxidation and Calpain-1/2, Matrix Metalloproteinase-2/9, and Rho A Overactivation. *Stroke* 42 11: 3238-3244.
- Moustafa RR, Momjian-Mayor I, Simon Jones P, Morbelli S, Day DJ, et al. (2011) Microembolism Versus Hemodynamic Impairment in Rosary-Like Deep Watershed Infarcts: A Combined Positron Emission Tomography and Transcranial Doppler Study. *Stroke* 42: 3138-3143.
- Klopfenstein JD, Ponce FA, Kim LJ, Albuquerque FC, Nakaji P, et al. (2005) Middle cerebral artery stenosis: endovascular and surgical options. *Skull Base* 15: 175-189.
- Hashmi JT, Huang YY, Osmani BZ, Sharma SK, Naeser MA, et al. (2010) Role of low-level laser therapy in neurorehabilitation. *PM R* 2: S292-305.
- Naeser MA, Hamblin MR (2011) Potential for transcranial laser or LED therapy to treat stroke, traumatic brain injury, and neurodegenerative disease. *Photomed Laser Surg* 29: 443-446.
- Song S, Zhou F, Chen WR (2012) Low-level laser therapy regulates microglial function through Src-mediated signaling pathways: implications for neurodegenerative diseases. *J Neuroinflammation* 9: 219.
- Stephan W, Banas LJ, Bennett M, Tunceroglu H (2012) Efficacy of super-pulsed 905 nm Low Level Laser Therapy (LLLT) in the management of Traumatic Brain Injury (TBI): A case study. *World Journal of Neuroscience* 2: 231-233.
- Konstantinović LM, Jelić MB, Jeremić A, Stevanović VB, Milanović SD, et al. (2013) Transcranial application of near-infrared low-level laser can modulate cortical excitability. *Lasers Surg Med* 45: 648-653.
- Takaiwa A, Kuwayama N, Akioka N, Kurosaki K, Hayashi N, et al. (2013) Effect of carotid endarterectomy on cognitive function in patients with asymptomatic carotid artery stenosis. *Acta Neurochir (Wien)* 155: 627-633.
- Altinbas A, Algra A, Brown MM, Featherstone RL, Kappelle LJ, et al. (2014) Effects of carotid endarterectomy or stenting on hemodynamic complications in the International Carotid Stenting Study: a randomized comparison. *Int J Stroke* 9: 284-290.
- Muroi C, Khan N, Bellut D, Fujioka M, Yonekawa Y (2011) Extracranial-intracranial bypass in atherosclerotic cerebrovascular disease: report of a single centre experience. *Br J Neurosurg* 25: 357-362.
- Papanagioutou P, Roth C, Walter S, Behnke S, Grunwald LQ, et al. (2011) Carotid artery stenting in acute stroke. *J Am Coll Cardiol* 58: 2363-2369.
- Matsumaru Y, Tsuruta W, Takigawa T, Hyodo A, Sato H, et al. (2004) Percutaneous transluminal angioplasty for atherosclerotic stenoses of intracranial vessels. *Interv Neuroradiol* 10 Suppl 2: 17-20.
- Derdeyn CP, Chimowitz MI (2007) Angioplasty and Stenting for Atherosclerotic Intracranial Stenosis: Rationale for a Randomized Clinical Trial. *Neuroimaging Clin N Am*. 17 3: 355-363.
- Dorn F, Prothmann S, Wunderlich S, Liebig T (2012) Stent angioplasty of intracranial stenosis: single center experience of 54 cases. *Clin Neuroradiol* 22: 149-156.
- Maksimovich IV (2013) Transcatheter Treatment of Patients after Extensive Ischemic Stroke. *J Am Coll Cardiol* 62 18 S1 155.
- Morris JC (1993) The Clinical Dementia Rating (CDR): current version and scoring rules. *Neurology* 43: 2412-2414.
- Folstein MF, Folstein SE, McHugh PR (1975) "Mini-mental state". A practical method for grading the cognitive state of patients for the clinician. *J Psychiatr Res* 12: 189-198.
- Mahoney FI, Barthel DW (1965) Functional evaluation: the barthel index. *Md State Med J* 14: 61-65.
- Maksimovich IV (2006) Method for carrying out transluminal laser-induced brain revascularization in atherosclerotic injury cases. RF Patent No. 2297861.
- Maksimovich IV (2006) Method of transluminal laser revascularization of cerebral blood vessels having atherosclerotic lesions. US Patent No. 7490612.
- Maksimovich IV (2015) TCT-757 Intracerebral Transcatheter Technologies in the Treatment of Ischemic Stroke. *J Am Coll Cardiol* 66: 308.
- Deviatkov ND, Rabkin IKh, Maksimovich IV, Rogov RA, Aleinikov VS (1986) Use of copper-vapor laser radiation for the evaporation of atherosclerotic lesions of the major arteries in vitro. *Surgery* 4: 116-121.
- Petrovskiy BV, Deviatkov ND, Rabkin IKh, Maksimovich IV, Rogov KA (1986) Destruction of arteriosclerotic lesions of human cadaveric arteries by laser irradiation with copper vapors. *Khirurgija* 5: 112-116.

34. Kuleshov EV, Maksimovich IV (1994) Endovascular surgery in patients over 65 with disseminated atherosclerosis of the vessels of the pelvis and lower extremities. *Vestn Khir Im I I Grek* 152: 27-30.
35. Maksimovich IV (2004) Transluminal laser angioplasty in treatment of ischemic lesions of a brain. M.D. Dissertation, Russian University of Friendship of the People, Moscow.
36. Chizhov GK, Koval'skaia NI, Kozlov VI (1991) The effect of helium-neon laser radiation on the energy metabolic indices of the myocardium. *Biull Eksp Biol Med* 111: 302-305.
37. Kozlov VI, Azizov GA (2007) Pathophysiological characteristics of microcirculatory disorders in chronic arterial ischaemia of lower limbs. *Angiol Sosud Khir* 13: 17-23.
38. Moskvina SV (2008) System analysis of efficiency in controlling biological systems with low-energy laser radiation. *World Journal of Neuroscience* 5.
39. Mak MC, Cheing GL (2012) Immediate effects of monochromatic infrared energy on microcirculation in healthy subjects. *Photomed Laser Surg* 30: 193-199.
40. Barrett DW, Gonzalez-Lima F (2013) Transcranial infrared laser stimulation produces beneficial cognitive and emotional effects in humans. *Neuroscience* 230: 13-23.
41. Yang X, Askarova S, Sheng W, Chen JK, Sun AY, et al. (2010) Low energy laser light (632.8 nm) suppresses amyloid- β peptide-induced oxidative and inflammatory responses in astrocytes. *Neuroscience* 171: 859-868.
42. Starck T, Nissilä J, Aunio A, Abou-Elseoud A, Remes J, et al. (2012) Stimulating brain tissue with bright light alters functional connectivity in brain at the resting state. *World Journal of Neuroscience* 2: 81-90.
43. Heinrich C, Blum R, Gascón S, Masserdotti G, Tripathi P, et al. (2010) Directing astroglia from the cerebral cortex into subtype specific functional neurons. *PLoS Biol* 8: e1000373.