

Record of an Abnormal *Schizothorichthys esocinus* (Heckel) from the Himalayan River Chenab Draining Jammu Region of the J&K State, India

Dutta SPS*

Emeritus Fellow (UGC), Departmental of Environmental Sciences, University of Jammu, Jammu, Jammu and Kashmir, India

Abstract

Two deformed Specimens of *Schizothorichthys esocinus* were observed among the fish collections from the river Chenab and is the first record for any Himalayan stream. One specimen was recognised by its flat caudal fin base and widely spaced caudal fin lobes. The other showed the post dorsal truncated body with a trough, ventral anal bulge and dome in the caudal peduncle region. X-ray analysis revealed hook shaped vertebral column and aberrations in the various vertebrae and caudal fin bones. Possible cause of aberrations in torrential non polluted river is mechanical injury induced by currents during embryonic development.

Keywords: *Schizothorichthys esocinus*; River Chenab; Akhnoor; Abnormalities

Introduction

An important food fish *Schizothorichthys esocinus* is widely distributed in cold water streams in the Himalayas. In the river Chenab, an important Himalayan river draining Jammu region, this fish is widely distributed from Doda to Pargwal wetland. During its hydrobiological study, over a period of three years, two adult deformed specimens of *S. esocinus* were noticed among the collections made by fishermen in Akhnoor area and is the first record of this deformed fish from any Himalayan stream in India and its neighbouring countries.

Materials and Methodology

Two deformed specimens of *S. esocinus* were purchased from fishermen in Akhnoor area and studied for morphological aberrations. For detailed skeletal deformities, these fishes along with normal specimens were exposed to X-rays (Rays, India, Digital X-ray machine).

Observation

Deformed specimens of *Schizothorichthys esocinus* seen in the collections made by the fishermen in the river Chenab are described as below (Figures 1-4).

Schizothorichthys esocinus showing flat caudal peduncle and widely spaced caudal fin lobes

This aberrant specimen of *Schizothorichthys esocinus*, measuring 25.9 cm and weighing 198 gm, was recognised by its flat caudal fin base and widely spaced caudal fin lobes. General body shape and placement of fins and number of fin rays in various fins viz. dorsal, pectoral, pelvic anal and caudal in this aberrant fish is like a normal fish (Figures 1 and 3). There is no deviation in various body ratios of normal and abnormal fish.

X-ray analysis has revealed normal shape of vertebral column, vertebrae, urostyle and caudal fin bones. However, caudal fin lobes are widely spaced in this abnormal fish (Figures 2 and 4).

Schizothorichthys esocinus showing post dorsal truncated body with a trough, ventral anal bulge and a dome in the caudal peduncle region

In a normal streamlined fish placement of dorsal fin is more towards the snout than the caudal fin base (Figure 1). In this aberrant fish, measuring 18 cm and weighing 85 g, placement of dorsal fin is



Figure 1: Photograph of a normal specimen of *Schizothorichthys esocinus* (Heckel).

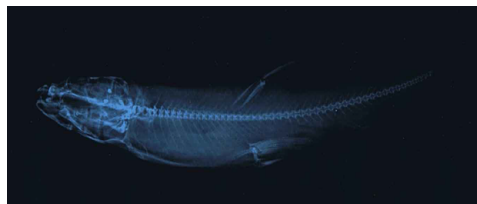

Figure 2: X-ray photograph of a normal specimen of *Schizothorichthys esocinus* (Heckel).



Figure 3: Photograph of *Schizothorichthys esocinus* (Heckel) showing flat caudal peduncle and widely spaced caudal fin lobes.

*Corresponding author: Dutta SPS, Emeritus Fellow (UGC), Departmental of Environmental Sciences, University of Jammu, Jammu, Tel: 01912431365; E-mail: spsdutta@gmail.com

Received November 05, 2015; Accepted November 30, 2015; Published February 15, 2016

Citation: Dutta SPS (2016) Record of an Abnormal *Schizothorichthys esocinus* (Heckel) from the Himalayan River Chenab Draining Jammu Region of the J&K State, India. J Aquac Res Development 7: 402. doi:10.4172/2155-9546.1000402

Copyright: © 2016 Dutta SPS. This is an open-access article distributed under the terms of the Creative Commons Attribution License, which permits unrestricted use, distribution, and reproduction in any medium, provided the original author and source are credited.

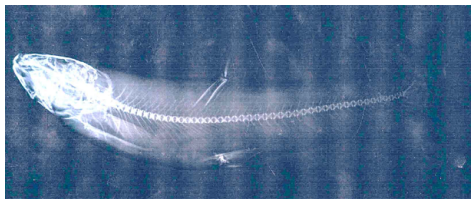


Figure 4: X-ray photograph of deformed specimen of *Schizothorichthys esocinus* (Heckel) showing flat caudal peduncle and widely spaced caudal fin lobes.



Figure 5: Photograph of *Schizothorichthys esocinus* (Heckel) showing post dorsal truncated body, a trough, a dome and anal bulge in the caudal peduncle region.

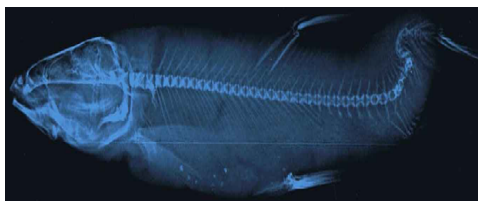

Figure 6a: X-ray photograph of *Schizothorichthys esocinus* (Heckel) showing post dorsal truncated body, a trough, a dome and anal bulge in the caudal peduncle region.



Figure 6b: Enlarged x-ray photograph of post dorsal region of deformed *Schizothorichthys esocinus* (Heckel).

more towards the caudal fin base than the snout. Like a normal fish there is a wide space between the extension of the longest pectoral fin ray and pelvic fin origin and extension of the longest pelvic fin ray and anal fin origin. In a normal fish, there is a wide gap between longest anal fin ray extension and caudal fin base and caudal fin is bilobed. On the contrary, in this deformed specimen of *Schizothorichthys esocinus* caudal peduncle is short, caudal fin lobes overlap and is not well demarcated and longest anal fin ray extends beyond the caudal fin base (Figure 5). There are some deviations in various body ratios of the normal and abnormal fish.

In normal and abnormal fish there are 46 and 42 vertebrae, respectively, after complex vertebrae, as revealed by X-ray analysis (Figures 2, 6a and 6b). Vertebral column in normal fish following the body shape is streamlined and has normal vertebral thickness, intervertebral spaces, ribs, neural and haemal spines and caudal bones. Vertebral column in this aberrant fish is normal upto 27th vertebrae. Posteriorly, vertebral column is directed upwards and forms a hook

shaped structure with aberrations in various vertebrae and are given as below:

- Vertebral column between 28th to 33rd vertebrae forms the base of the hook. 32nd and 33rd vertebrae are fused and opaque (ankylosis). Vertebrae degenerated and vertebral thickness and intervertebral spaces irregular. Neural and haemal spines overlap and not clear.
- Posteriorly, vertebral column between 39th-42nd vertebrae forms the head of the hook (scoliosis). Vertebral thickness and intervertebral spaces irregular. Spines not clear and overlap.
- Urostyle and caudal bones not clear.

From the X-ray analysis it is clear that post dorsal truncated body with a dorsal trough, ventral anal bulge and dorsal dome in caudal peduncle is due to hook shaped structure of the vertebral column (scoliosis) and aberrations in vertebrae viz. reduced vertebral thickness and intervertebral spaces.

Discussion

Records of only two deformed specimens of *S. esocinus* observed over a period of three years suggests that fish anomalies in this clean water river are rare. The other possibility is that deformed fishes are unable to survive in torrential waters. Collection of these two adult deformed fishes suggests that these aberrations are non fatal, feeding is normal and they are able to avoid predators.

Fish anomalies have been attributed to physical factors like temperature [1-3], fluctuations in one or the other chemical parameters like salinity, low dissolved oxygen, high carbon dioxide [4-8] and water quality degradation by pollutants [9-11].

Rare records of anomalous fishes and optimum level of various physico-chemical characteristics of water (Water temperature, 8-16°C; Transparency, nil-240 cm; Turbidity, 2.3-942.33 NTU; pH, 8.23-8.46; conductivity, 140.05-308.47 µS; total dissolved solids, 63.90-140.88 mg/l; salinity, 0.2 ppt; DO, 6.24-13.08 mg/l; BOD, 1.07-5.56 mg/l; Free CO₂ nil; carbonate, 1.16-3.97 mg/l; bicarbonate, 54.27-116.25 mg/l; chloride, 2.33-9.28 mg/l; calcium, 14.79-32.49 mg/l; magnesium, 3.87-10.13 mg/l; total hardness, 58.52-119.56 mg/l; sodium, 1.11-1.69 mg/l; potassium, 1.23-2.54 mg/l; phosphate, 0.040-0.075 mg/l; nitrate, 0.145-0.323 mg/l; silicate, 4.08-9.33 mg/l; sulphate, 11.35-19.30 mg/l and below detection level of chromium, nickel, zinc, lead and copper) suggests that these anomalies are not due to water quality degradation caused by pollutants.

Conclusion

Among physical factors, truncated shape of one specimen of *Schizothorichthys esocinus* is mostly probably due to fast currents in breeding grounds. This fish for breeding migrates into cold water torrential tributaries of the River Chenab. Aberrations in other specimen of *S. esocinus* with flat caudal fin base and widely spaced caudal fin lobes is due to some mechanical injury in fast flowing waters. Fish anomalies due to currents have also earlier been reported by Backiel et al. [12], Chaitan [13], Divanach et al. [14] and Dutta [15].

Acknowledgement

This paper is a part of the project sanctioned by the UGC, New Delhi, for which I express my thanks to the concerned agency. Emeritus Fellowship awarded by UGC, New Delhi, is gratefully acknowledged. HOD, Environmental sciences, University of Jammu is acknowledged for providing necessary facilities in the department. Thanks are due to Mr. R. K. Gandhi for his help in typing the manuscript.

References

1. Hubbs C (1959) High incidence of vertebral deformity in two natural populations of fishes inhabiting warm water springs. *Ecology* 40: 154-155.
2. Al-Hassan LAJ (1982) Vertebral deformities in fishes from Iraq and united Arab Emirates, Arabians, Gulf. *Iraqi J Mar Sci* 1: 13-23.
3. Wang LH, Tsai CL (2000) Effects of temperature on deformity and sex differentiation of Tilapia, *Oreochromis mossambicus*. *J Expt Zool* 286: 534-537.
4. Lee CH, WilliamWD (1970) Abnormality in fishes due to salinity fluctuations. *J Fish Biol* 2: 55.
5. Martens LG, Witten PE, Fivelstad S, Haysstune A, Sulvaried B, et al. (2006) Impact of high water carbon dioxide on Atlantic salmon smolts (*Salmo salar* L.) on fish performance, vertebral composition and structure. *Aquaculture* 261: 80-88.
6. Jawad LA, Oktner AO (2007) Incidence of lordosis in freshwater mullet, *Liza abu* (Heckel, 1843) collected from Ataturk lake, Turkey. *Anales de Biologia* 29: 105-113.
7. Lall SP, Lewis-McCrea LM (2007) Role of nutrients in skeletal metabolism pathology in fish: An overview. *Aquaculture* 267: 3-19.
8. Sun PL, Hawkins WE, Overstreet RM, Peterson BNJ (2009) Morphological deformities as biomarkers in fish from contaminated rivers in Taiwan. *Int J Envir Res Public Health* 6: 2307-2331.
9. Subla BR (2004) Anomalies in bighead carp, *Aristichthys nobilis* and African cat fish, *Clarias gariepinus*, in Baratinagar, Nepal. *Our Nature* 2: 41-44.
10. Kent ML, Watral VG, Whipps CM, Cunningham ME, Crisctone CD, et al. (2004) A Digenean metacercaria (*Apophallus* sp.) and a Myxozoan (*Myxobolus* sp.) associated with vertebral deformities in cyprinoid fishes from the Willamette River, Oregon. *J Aquat Ani Heal* 16: 116-129.
11. Villeneuve DL, Curtis LR, Jenkins JJ, Warner KE, Tilton F, et al. (2005) Environmental stress and skeletal deformities in fish from the Willamette River, Oregon. *Environ Sci Technol* 39: 3495-3506.
12. Backiel J, Kokurewicz B, Ogorzalek A (1984) High incidence of skeletal anomalies in Carp, *Cyprinus carpio*, reared in cages in runing water. *Aquaculture* 43: 369-380.
13. Chaitan B (1994) Abnormal swim bladder development and lordosis in sea bass (*Dicentrachus labrax*) and sea bream (*Sparus auratus*). *Aquaculture* 119: 371-379.
14. Divanach P, Papandroulakis N, Anastasiadis P, Koumoundouros G, Kentouri M (1997) Effects of water currents on the development of skeletal deformities in sea bass (*Dicentrachus labrax* L.) with functional swim bladder during post larval and nursery phase. *Aquaculture* 156: 145-155.
15. Dutta SPS (2012) Limnology of the river Chenab, at Akhnoor, Jammu. Part II deformities in *Schizothoracichthys esocinus* (Heckel) *Tor putitora* (Ham-Buch) *Tor tor* (Ham-bach) *Labeo rohita* (Ham-Bcah) and *Mystus bleekeri* (Day) Project Report, submitted to the UGC, New Delhi, India.