

## ADD-Care® - A Natural Alternative!

Jef Gazley\*

LMFT, USA

\*Corresponding author: Jef Gazley, 6540 E. Kelton Lane, Scottsdale, Arizona 85254, USA, Tel: 866-998-0560; E-mail: jef@asktheinternettherapist.com

Received Date: July 08, 2014, Accepted Date: October 28, 2014, Published Date: November 5, 2014

Copyright: © 2015 Jef Gazley, This is an open-access article distributed under the terms of the Creative Commons Attribution License, which permits unrestricted use, distribution, and reproduction in any medium, provided the original author and source are credited.

### Short Communication

Attention Deficit Disorder is a condition that is characterized by an imbalance in the neurotransmitters in the brain. Neurotransmitters are brain chemicals that carry feelings and thoughts in an interactive loop between the body and mind. The main neurotransmitters are Norepinephrine, Acetylcholine, and Dopamine, which are the stimulating brain chemicals that add brightness, energy, and focus to the brain. GABA is the brain chemical that slows the brain down and makes it calmer. Serotonin is the neurotransmitter that helps with depression and promotes sleep. In general food, vitamins, and supplements turn into hormones which turn into the neurotransmitters.

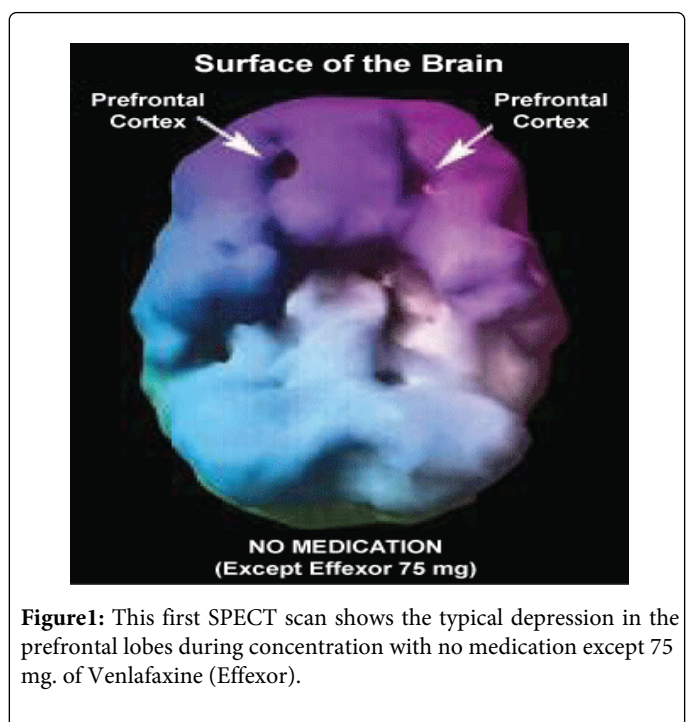
In the treatment of ADD or any mental health issue there is a choice between using supplements as precursors to raise the neurotransmitters or chemicals to alter the amount in what is usually a harsher fashion. The track record of natural treatment for Attention Deficit Disorder has been very poor until ADD-care®. The components of ADD-care are a homeopathic proprietary blend of Humulus, Aesculus, Oenanthe, Aconite, and Gelsemium, and GABA 165 mg. and L-Tyrosine 335 mg. However, the first series of scans were done only with the homeopathic blend.

In 2007 ADD-care® was compared in head to head comparisons with amphetamine sulfate (Adderall) at the prestigious Amen Clinic. Both SPECT brain imaging and the Conner's test were administered. The amazing results are listed below.

ADD-care® has been shown, by SPECT scans to add blood flow and electrical activity to the prefrontal cortex of the brain which increases focusing and is the part of the brain that is positively affected by the stimulants such as Ritalin. ADD-care® also has been demonstrated by brain imaging to raise Dopamine, Acetylcholine, GABA, and Serotonin. It is the ability to boost and balance these neurotransmitters that makes ADD-care® so effective.

What is truly amazing is that ADD-care® does this naturally without adversely affecting sleep or appetite. It actually calms and focuses without anxiety or irritability. And because it is all natural, no prescription is necessary, making ADD-care® much more cost effective than the stimulants.

Originally this patient was stabilized on 150 mg. of Venlafaxine (Effexor) and 20 mg. of Amphetamine Sulfate (Adderall) BID for two years. He reduced his Venlafaxine (Effexor) several weeks before the test to 75 mg. and was on that amount throughout the entire 3 days of testing.

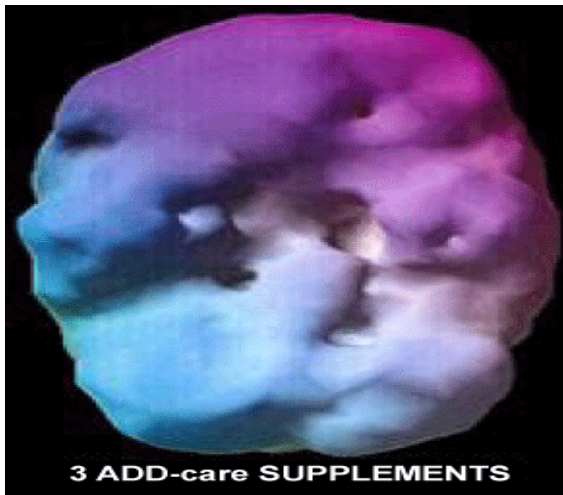

**Figure1:** This first SPECT scan shows the typical depression in the prefrontal lobes during concentration with no medication except 75 mg. of Venlafaxine (Effexor).

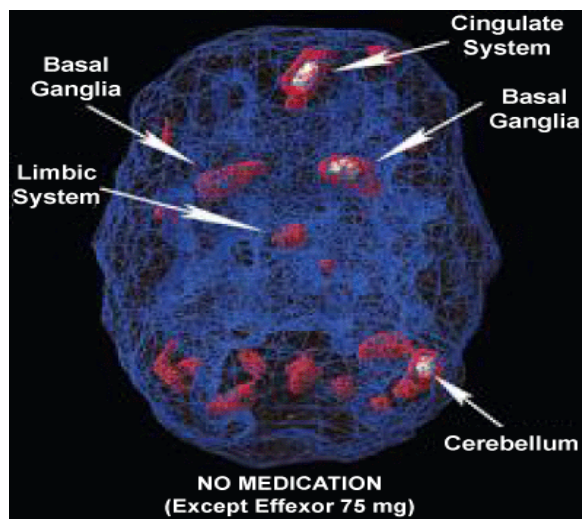
The following are four case study comparisons of clients who did not use medication the day of the first day of the testing, ADD-care the second day, and Adderall the third day using SPECT brain imaging and Conner's testing.

### Spect Scan 1

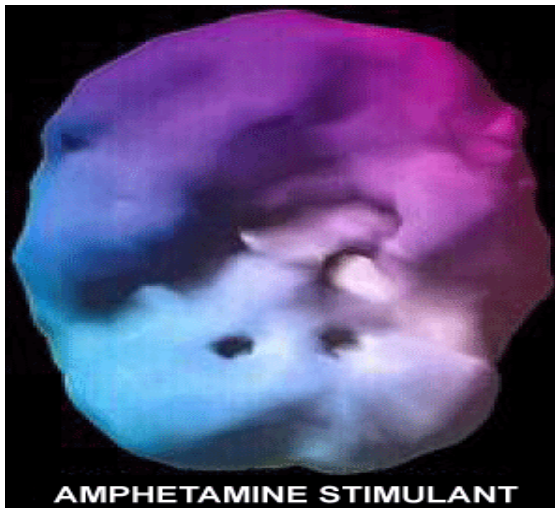This series of scans is from a 36 year old male with over-focused, limbic, and inattentive Attention Deficit Disorder or ADD (Figures 1-6).



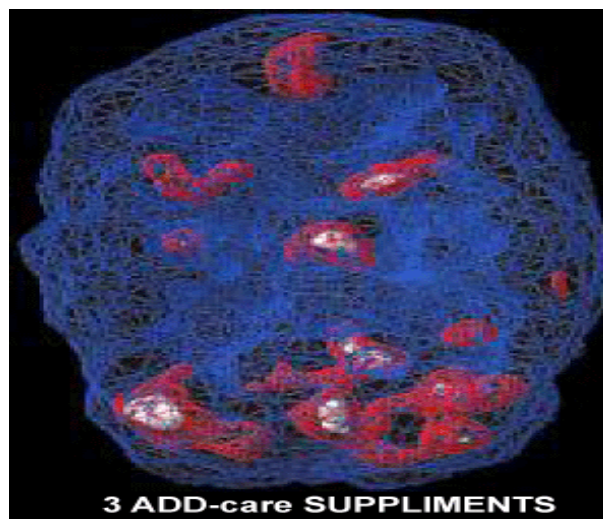
**Figure 2:** During the second scan he took three capsules of the supplement and the left lobe cleared completely and the right lobe cleared by 85-90%.



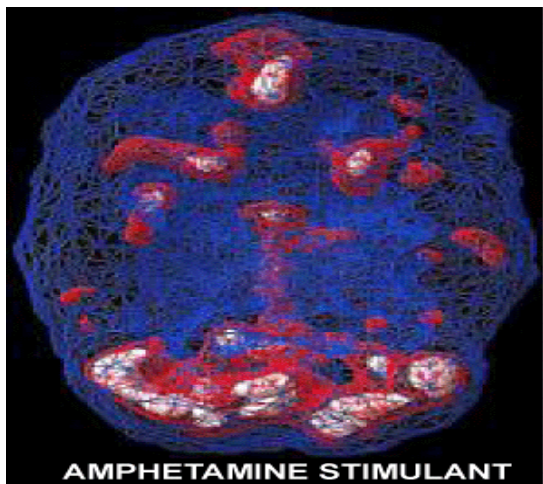
**Figure 4:** This series of scans focuses on the internal parts of the brain. The lower part of the brain called the cerebellum should be all white showing good Dopamine activity. As you can see his brain without any medication other than 75 mg. of the antidepressant had only a sliver of white at the extreme right.



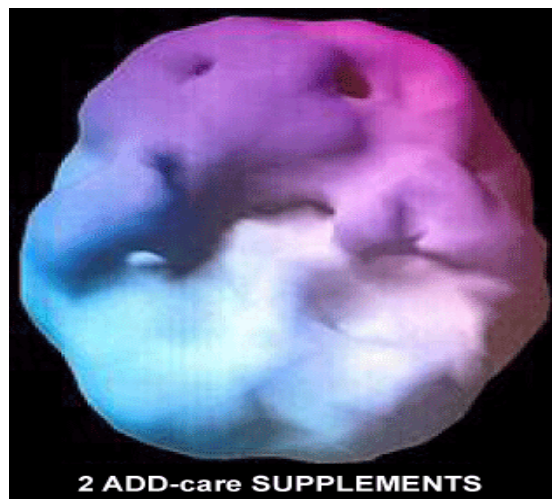**Figure 3:** The third scan was administered with 20 mg. of Adderall. The entire prefrontal cortex is almost completely smooth with the exception of a shallow depression in the right lobe. It was cleared by 90-95%. Overall, ADD-care® performed about 80-95% as well as the stimulant on the surface scans.



**Figure 5:** In the supplement scan the limbic system is decreased by more 70% and the basal ganglia have been reduced by 80-85%. The cingulate system is totally clear. The cerebellum is showing significantly more activity.



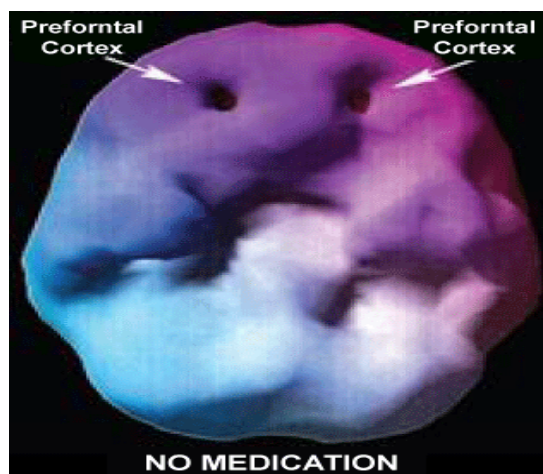
**Figure 6:** The third scan with 20 mg. of Adderall increased the cerebellum significantly, but the limbic system stayed inflamed. The cingulate system became grossly inflamed and the basal ganglia on the right increased significantly and the left basal ganglia became inflamed.



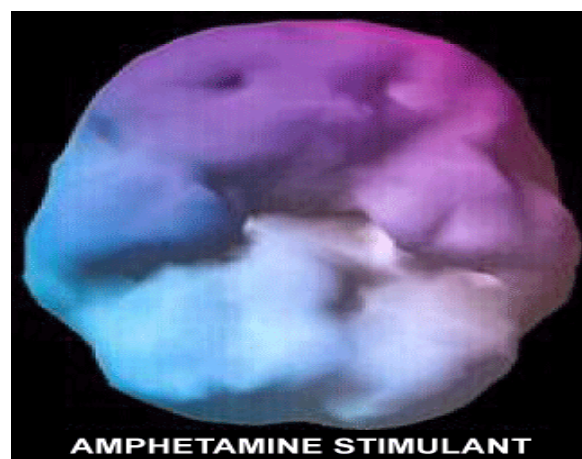**Figure 8:** This second scan is the same brain and the same concentration task with two capsules of the supplement ADD-care®. The left lobe is almost completely smooth, the right lobe has improved by 40-50%, and the whole brain is smoother and fuller

### Spect Scan 2

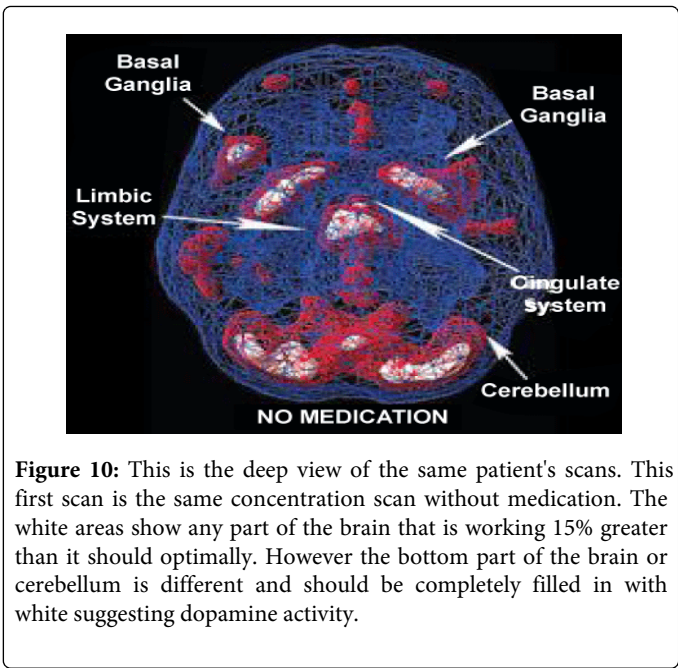
This series of scans belong to a 36 year old female that has taken amphetamine sulfate (Adderall) for over 5 years for Attention Deficit Disorder (ADD).



**Figure 7:** This SPECT scan shows the typical prefrontal cortex of an ADD patient who is concentrating without any medication. It clearly shows the deep pockets where the brain has essentially gone to sleep and is unable to focus.

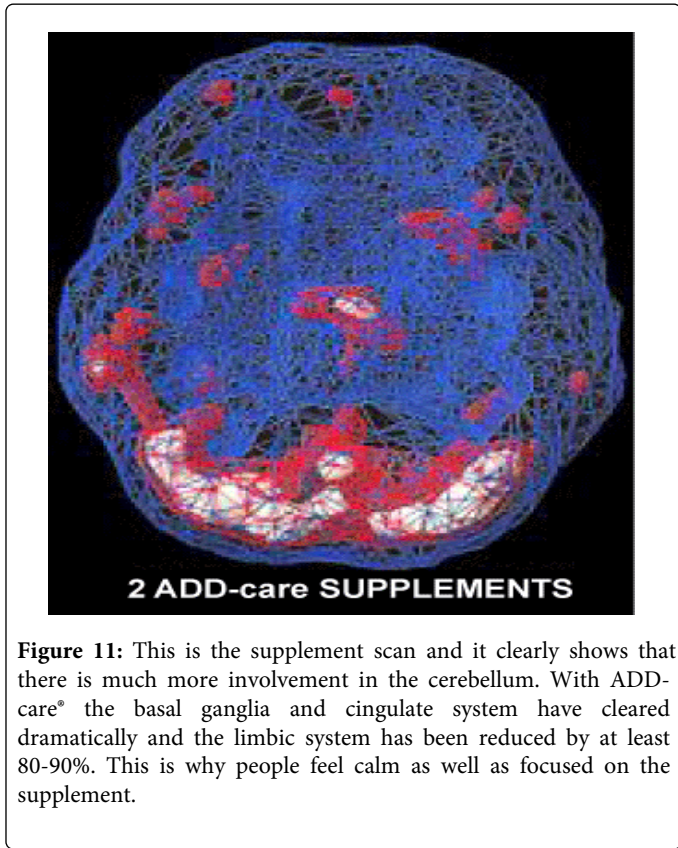


**Figure 9:** The third scan is with 20 mg. SR of the amphetamine during concentration. The left lobe is not quite as good as the ADD-care® scan, but the right lobe is about 40% better. The supplement performed at roughly 75% to 85% as well as the popular stimulant for prefrontal activity.

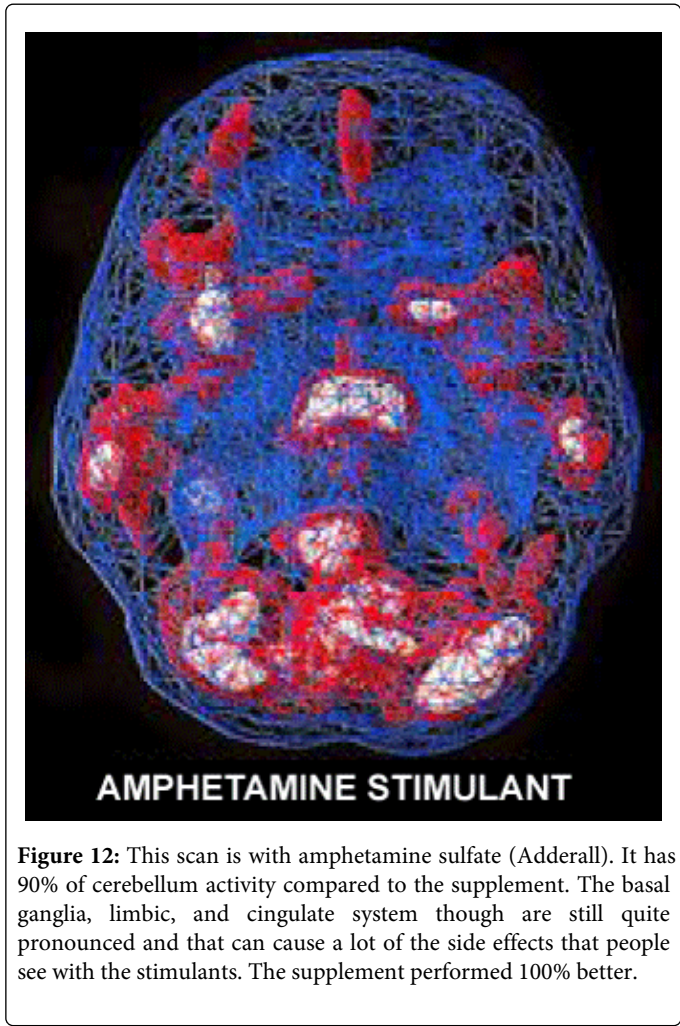


**Figure 10:** This is the deep view of the same patient's scans. This first scan is the same concentration scan without medication. The white areas show any part of the brain that is working 15% greater than it should optimally. However the bottom part of the brain or cerebellum is different and should be completely filled in with white suggesting dopamine activity.

The two large white areas on either side of center are the basal ganglia. The middle section is the limbic system. The cingulate system often appears like a Mohawk haircut running up and down the full length of the middle of the brain. At the top of the limbic system the small white area indicates that the cingulate system is also over-activated.



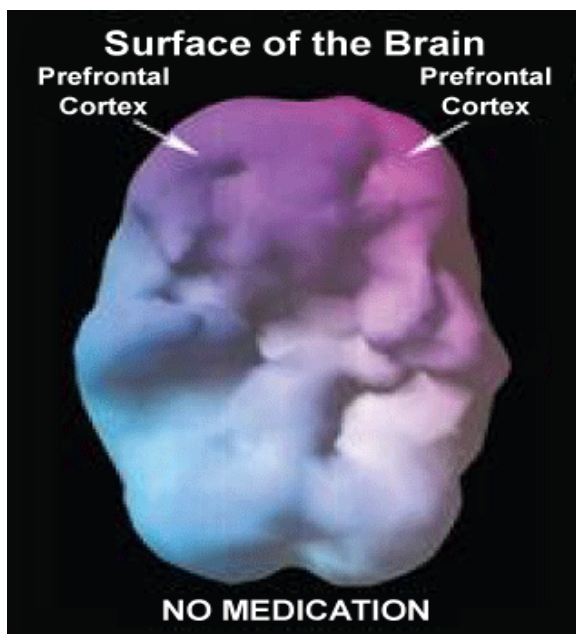
**Figure 11:** This is the supplement scan and it clearly shows that there is much more involvement in the cerebellum. With ADD-care® the basal ganglia and cingulate system have cleared dramatically and the limbic system has been reduced by at least 80-90%. This is why people feel calm as well as focused on the supplement.



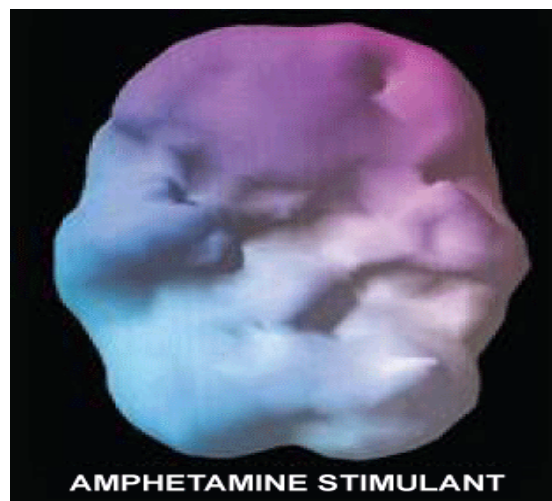
**Figure 12:** This scan is with amphetamine sulfate (Adderall). It has 90% of cerebellum activity compared to the supplement. The basal ganglia, limbic, and cingulate system though are still quite pronounced and that can cause a lot of the side effects that people see with the stimulants. The supplement performed 100% better.

**Spect Scan 3**

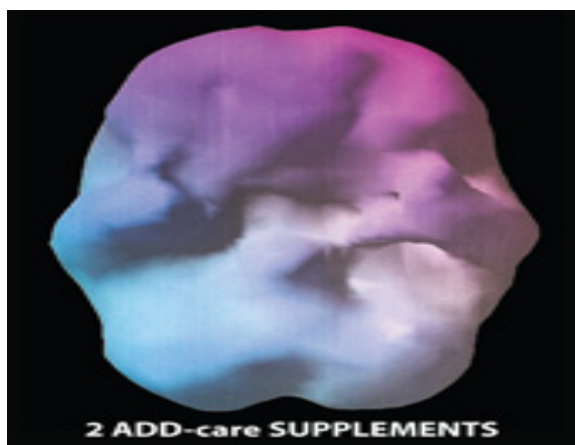(Figures13-18)



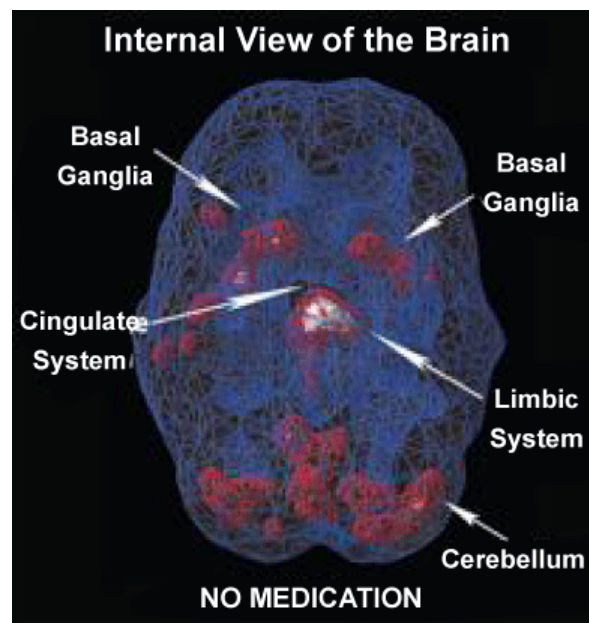
**Figure 13:** This is the unmedicated SPECT scan of a 44 year old woman suffering from over-focused Attention Deficit Disorder (ADD) who was using 30 mg. of Adderall for over a year. Both hemispheres of the prefrontal cortex show the deep pockets that are typical for ADD. These pockets depict decreased blood flow which results in a lack of focus and impulsivity.



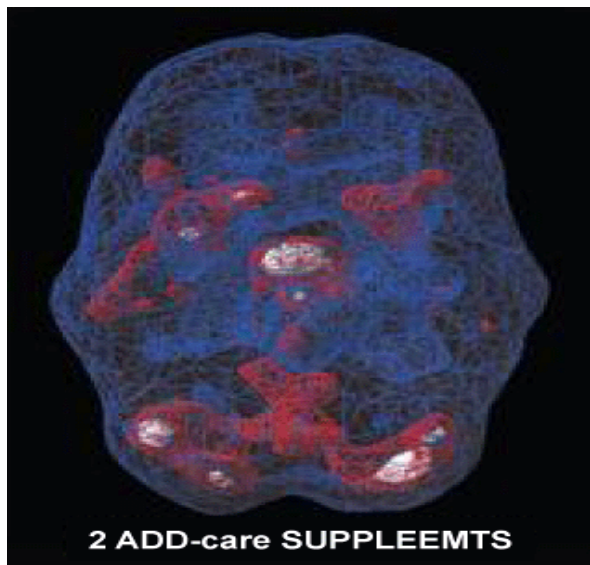
**Figure 15:** The third surface scan shows the same client with 30 mg. SR of amphetamine sulfate (Adderall). The left lobe is smooth and regular, but the right lobe has a deep pocket showing decreased activity. ADD-care® was at least 20% more effective in the prefrontal cortex area.



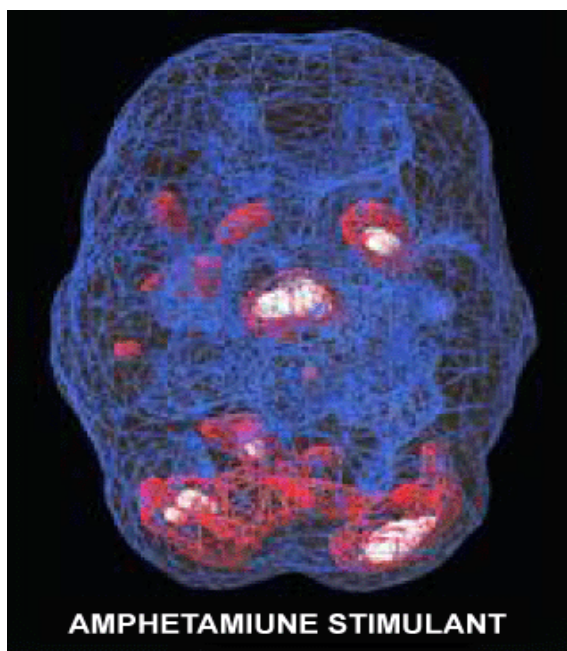
**Figure 14:** This second surface scan is the same woman with 2 capsules of ADD-care®. The pockets are gone and the two hemispheres are smooth and symmetrical which indicates tremendous improvement of her ADD.



**Figure 16:** This is the unmedicated scan of the same client, but shows the deeper part of her brain. There is only a sliver of white in the cerebellum at the bottom. There is some basal ganglia inflammation on the left and significant problems in the limbic system.



**Figure 17:** The scan with 2 capsules of ADD-care® shows significant improvement in the cerebellum. The rest of the brain shows essentially no change from the unmedicated scan.

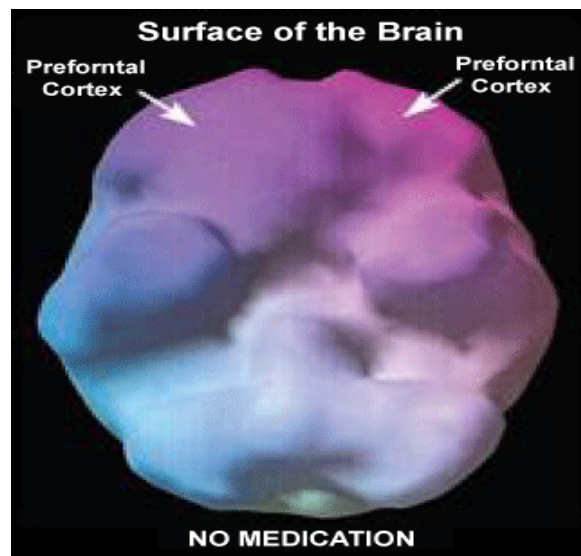


**Figure 18:** This is the 30 mg. stimulant (Adderall SR) deep scan. The limbic system is 5-10% more inflamed than on the ADD-care® scan and the right basal ganglia is impaired while the ADD-care® scan had full functioning.

The next series of brain SPECT scans are from a 58 year old woman who was complaining of memory problems, challenges with direction, difficulty learning, and time management issues since childhood. Since menopause these problems had become worse and she had become lethargic as well. She wondered if she had Attention Deficit Disorder or ADD. Figures 19-24.

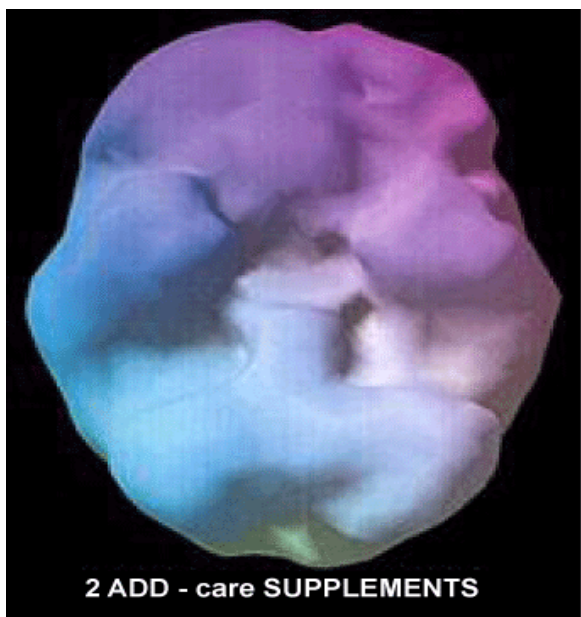
During each scan the Conner's ADD test was administered. During the first scan she missed 4.44, the second scan missed 4.44, and the third scan the patient missed 4.44 so there was no difference noted on performance between the three groups although Janice stated subjectively that she was more focused and calm with ADD-care®.

The traditional role of a natural supplement is to support the basic structure of the body and ADD-care® certainly seems to do this. What is truly amazing is that based on the results of this study ADD-care® goes further suggesting it may actually rival the results of the traditional treatment for Attention Deficit Disorder [1-6].

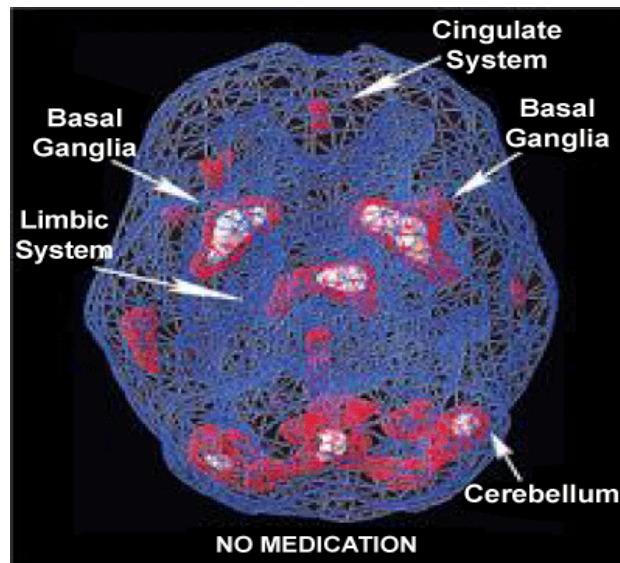


**Figure 19:** The first surface scan without medication and with concentration did not show the typical ADD pattern of pockets in the prefrontal cortex, but did show a very slight indentation in the right side.

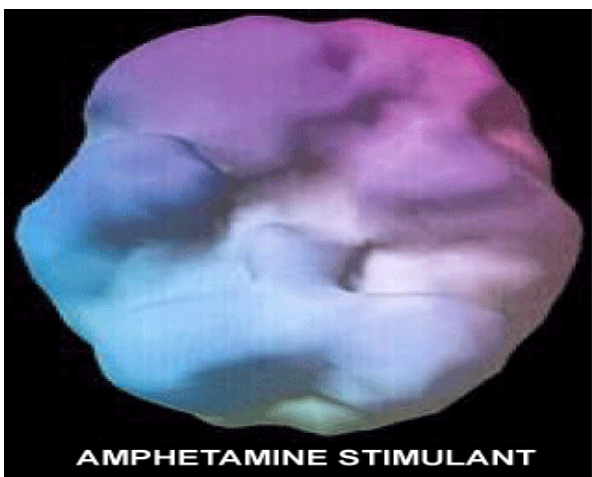#### Spect Scan 4



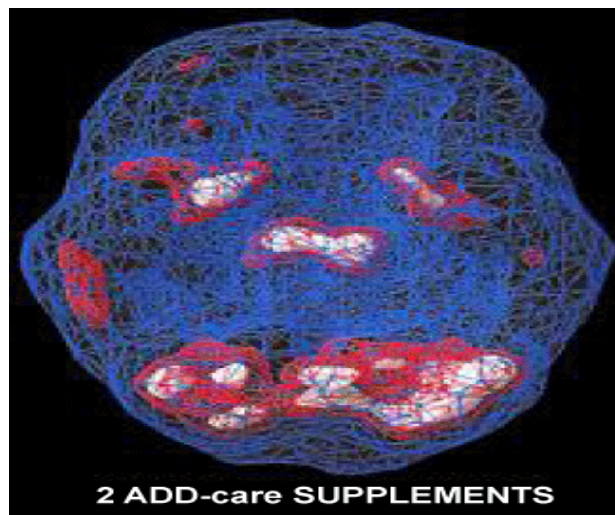
**Figure 20:** The second surface scan with the supplement showed essentially the same pattern with a slight indentation in the right lobe.



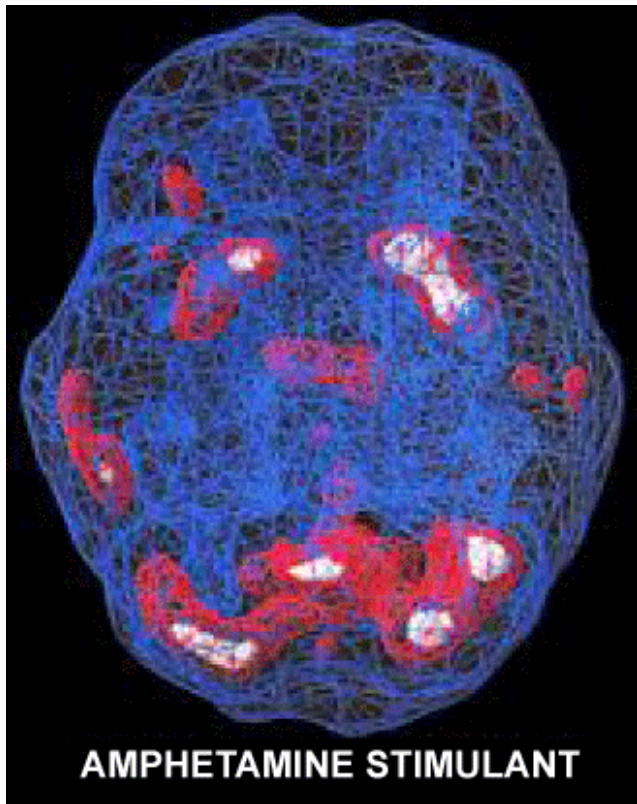
**Figure 22:** The first deep scan with no medication and concentration showed very little activity in the cerebellum, which meant that very little Dopamine was present. Dopamine depletion is a huge component in attention deficit disorder and memory. The limbic system is inflamed and both basal ganglia are quite enlarged showing depression and anxiety.



**Figure 21:** The third surface scan with a popular stimulant showed the same pattern so ADD-care® was comparable.



**Figure 23:** The second deep scan with the supplement showed a huge improvement in Dopamine in the cerebellum with the ADD-care® supplement. The basal ganglia on the left was reduced by 60% and the one on the right was reduced by 75%. The limbic system was increased by 50%.



**Figure 24:** The third deep scan with amphetamine sulfate (Adderall) 20 mg. SR showed only moderate improvement in the cerebellum from the first scan and not nearly as good as ADD-care®. The limbic system was significantly improved however vs. the supplement. Basal ganglia activity on the left was 70% better with the popular stimulant, but the right was 75% better with ADD-care®.

During each scan the Connors ADD test was administered. During the first scan the patient missed 9 items and on the last two scans the patient missed no items so ADD-care® matched the popular stimulant on performance.

## References

1. Amen Dr Daniel G (2000) Change Your Brain Change Your Life. New York. Times Books.
2. Amen Dr. Daniel G (2001) Healing ADD The Six Types. New York. G.P. Putnam's Sons.
3. Amen Dr Daniel G (2003) Healing Anxiety and Depression. New York. G.P. Putnam's Sons.
4. Gazley Jef (2012) Attention Deficit Disorder and ADD-care® The Natural Alternative! There Is Never a Reason To Be Without a Prefrontal Cortex. Scottsdale, AZ. Internet Therapist Publishing.
5. Hallowell E (1995) Driven To Distraction: Recognizing And Coping With Attention Deficit Disorder From Childhood Through Adulthood. Austin, Texas. Touchstone Books.
6. Hallowell E (2005) Delivered From Distraction: Getting The Most Out Of Life With Attention Deficit Disorder. New York. Ballantine Books.