

Benign Migratory Glossitis (Lingual Erythema Migrans)

Irena V Fisenko*

Head of Dental Section, Royal Hospital, Ministry of Health, Oman, Muscat

*Corresponding author: Dr. Irena V Fisenko, Head of Dental Section, Royal Hospital, Ministry of Health Oman, Muscat, Jawaharat Al-Shatie Oman, Tel: +968 99356064; E-mail: Dr.Irena.ODC@gmail.com

Received date: December 12, 2018; Accepted date: December 29, 2018; Published date: January 01, 2019

Copyright: © 2018 Fisenko IV, et al. This is an open-access article distributed under the terms of the Creative Commons Attribution License, which permits unrestricted use, distribution, and reproduction in any medium, provided the original author and source are credited.

Abstract

Benign Migratory Glossitis affects only a small fraction of the general population (1-3%) with a female predilection and should be distinguished from other benign and malignant conditions affecting oral mucosal and the tongue. With the mounting research in recent years, this condition has been found to have a certain correlation with some immunological conditions in terms of clinical association and histopathological findings, as well as in terms of sharing common immunohistochemical markers and genetic components, all of which have bearing on its diagnosis and clinical approach and management.

Keywords: Oral medicine; Oral lesion; Benign oral lesion

Introduction

Benign Migratory Glossitis (BMG) or lingual erythema migrans, which is also commonly known as “geographic tongue” due to its unique wavy and changing “map-like” clinical pattern, is an uncommon oral condition believed to be affecting 1-3% of the general population [1]. Jainkittivong A [2] based on his study of 188 individuals, reported highest occurrence of the lesion in 20-29-year-olds (39,4%) with female predominance (1.5:1), while Shulman JD, [3] who conducted a survey of 10,030 individuals, reported the prevalence of this condition being greater in males over females (11,76% over 8,67% respectively).

With the established tendency to rarely cause any symptoms, its chronic character, migratory nature, spontaneous resolution and recurrence, the etiology and pathology of this lesion still remains not clearly understood. In recent years there is accumulated research pointing to the correlation of BMG with certain immunological conditions in terms of clinical association, correlation of histopathological findings, common immunohistochemical markers and genetic components [4].

Comments to the Image

A 21-year-old male patient with the history of complex congenital heart disease and multiple previous cardiac surgical interventions who was on daily Allopurinol and a prophylactic dose of Aspirin presented to the dental clinic for a routine follow-up exam. He had no dental complaints but was concerned with the unusual pattern on his tongue that had a tendency to change its appearance and color with time, disappear completely and reappear with no associated symptoms.

The patient did not report any known allergies or habits, had no recent oral viral or infection and/or oral lesions. On clinical examination, he was found to have fair oral hygiene, caries-free dentition, healthy gingivae, and oral mucosae. Lingual examination revealed erythematous well-defined depapillated patches on the dorsum and lateral borders of the tongue with well-demarcated irregular whitish borders-the clinical pattern consistent with Benign

Migratory Glossitis (lingual erythema migrans) aka geographic tongue (Figure 1). Routine complete blood count, blood glucose test and metabolic profile were performed and all found to be within the norm, thus eliminating possible underlying anemia, diabetes mellitus and/or nutritional deficiency.

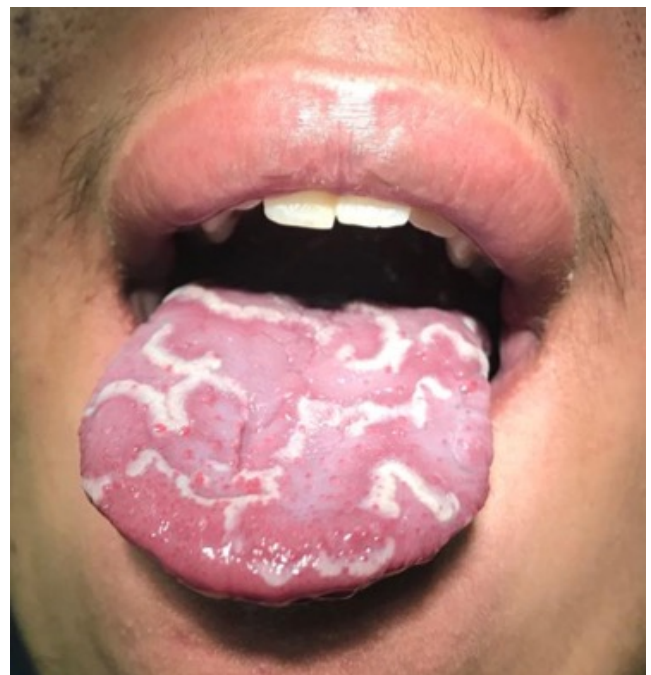


Figure 1: Geographic tongue.

Discussion

Benign Migratory Glossitis (BMG) usually characterized by presentation of erythematous areas of filiform papillae atrophy (depapillation) that may present as ulcer-like patches surrounded by slightly elevated hyperkeratotic serpiginous (wavy) pattern of the

irregular border on the dorsum and/or lateral borders of the tongue which is migratory by nature thus the attributed names annulus migrans and wandering rash [5]. The lesion could be solitary or continuous (occupying the entire dorsal and/or lateral surface of the tongue), it is of chronic but often transient character with periods of remission and complete resolution and exacerbation and relapse. While usually asymptomatic, this lesion can occasionally be associated with sensitivity or burning sensation on acidic, spicy and hot foods [6].

In recent years there has been a number of reports referencing statistically significant correlation of BMG occurrence in patients with immunologically-mediated conditions such as psoriasis [7] and chronic granulomatous disease [8] as well as its strong association with fissured tongue although its inverse association with smoking [9]. According to the results of the study conducted by Morris LF, et al. [10], as many as 10,3% of patients with psoriasis presented with BMG comparing to 2,5% of age and gender-matched control patients possibly suggesting it being an intra-oral presentation of psoriasis. In the study by Alikhani M. et al., [11] on 170 participants, immunologic parameters among others were found to be associated with Geographic Tongue (GT) as well.

BMG is a benign self-limiting often asymptomatic condition with no lasting complications or sequelae. However, it does warrant differential diagnosis with a wide range of oral conditions including oral cancers, lichen planus, leukoplakia, systemic lupus erythematosus, mucosal candidiasis, recurrent aphthous stomatitis, viral oral lesions (e.g. Herpes Simplex), vitamin deficiency glossitis, drug reaction, and even chemical burns. History of the lesion's occurrence and behavior, its clinical presentation and migratory pattern, exclusion of underlying immunological and nutritional deficiencies/conditions and, when required, oral biopsy with histopathology exam can all help in establishing the definitive diagnosis [12].

Due to the benign nature of the lesion, patients usually require no treatment with reassurance being the main approach. If symptomatic, patients are advised to avoid contacts with irritants and maintain good oral hygiene. In mild cases, patients may have relief from topical application of oral anesthetic and corticosteroids gels or solutions, or topical and systemic antihistamine [13]. While in more severe cases, treatment with topical and systemic immunosuppressant medications such as Tacrolimus or Cyclosporine may prove beneficial [14]. If associated with psoriasis or another immune-mediating disease, the treatment would require greater complexity and coordination between respective health disciplines and professionals.

References

1. Madani FM, Kuperstein AS (2014) Normal variations of oral anatomy and common oral soft tissue lesions. evaluation and management. *Med Clin North Am* 98: 1281-1298.
2. Jainkittvong A, Langlais RP (2005) Geographic tongue: Clinical characteristics of 188 cases. *J Contemp Dent Pract* 6: 123-135.
3. Shulman JD (2005) Prevalence of oral mucosal lesions in children and youth in the USA. *Int J Paediatr Dent* 15: 89-90.
4. Bruna Lavinias SP, Domingos TA, Teixeira-Souza T, Vanessa de Carla, Sousa Gonzaga HF, et al. (2016) Geographic tongue and psoriasis: clinical, histopathological, immunohistochemical and genetic correlation-a literature review. *An Bras Dermatol* 91: 410-421.
5. Marks R, Radden BG (1981) Geographic tongue: A cunico-pathological review. *Austral J Dermatol* 22: 75-79.
6. Nupur S, Pratik K, Bhavna D, Princy T (2016) Geographic tongue: A case report with review of literature. *Advances in Human Biology* 6: 142-144.
7. Costa SC, Hirota SK, Takahashi MD, Andrade H, Migliari DA (2009) Oral lesions in 166 patients with cutaneous psoriasis: A controlled study. *Med Oral Patol Oral Cir Bucal* 14: e371-e375.
8. Dar-Odeh NS, Hayajneh WA, Abu-Hammad OA, Hammad HM, Al-Wahadneh AM, et al. (2010) Orofacial findings in chronic granulomatous disease: Report of twelve patients and review of the literature. *BMC Res Notes* 3: 37.
9. Shulman JD, Carpenter WM (2006) Prevalence and risk factors associated with geographic tongue among US adults. *Oral Dis* 12: 381-386.
10. Morris LF, Phillips CM, Binnie WH, Sander HM, Silverman AK, et al. (1992) Oral lesions in patients with psoriasis: A controlled study. *Cutis* 49: 339-344.
11. Alikhani M, Khalighinejad N, Ghalaiani P, Khaleghi MA, Askari E, et al. (2014) Immunologic and psychologic parameters associated with geographic tongue. *Oral Surg Oral Med Oral Pathol Oral Radiol* 118: 68-71.
12. Assimakopoulos D, Patrikakos G, Fotika C, Elisaf M (2002) Benign migratory glossitis or geographic tongue: an enigmatic oral lesion. *Am J Med* 113: 751-755.
13. Sigal MJ, Mock D (1992) Symptomatic benign migratory glossitis: Report of two cases and literature review. *Pediatr Dent* 14: 392-396.
14. Ishibashi M, Tojo G, Watanabe M, Tamabuchi T, Masu T, et al. (2010) Geographic tongue treated with topical tacrolimus. *J Dermatol Case Rep* 4: 57-59.