

Zirconia implants

Alain Clairet, Paris
 Bogdan Vladila, Bucuresti

Following the article published in previous number of journal, this article intends to present the progress brought by Zirconia Implants in Oral Health.

Zirconia Implants have a high degree of biocompatibility, having a very good mechanic resistance. Nowadays, it is considered the best choice in Oral Implantology because of its excellent reaction in contact with gingival tissue, the lack of plaque retention and the bio-active qualities (a big affinity for proteins active in bone formation, a big capacity to attract Calcium). Due to this qualities, the osseointegration appears after a very short period.

Having this qualities, implants could be loaded after a short healing period, taking into account all the security measurements necessary for healing.

The design of the new implant is presented in the following pictures.

There are available Zirconia Implants with different angulation for abutment which could be used in a second stage surgery technique (*figure 1*).

There are available implants for immediate loading, the monobloc implant has designs for different angulation of the abutments, the retention of implants inside bone is original. There is also the possibility to contour the gingival tissue around implant for obtaining a perfectly esthetic rehabilitation. The big advantage of Zirconia is the possibility to modelate the gingival and supragingival parts with a diamond bur with copious irrigation, and also Zirconia has the big advantage of heat isolation. The color of abutment is identique with natural teeth, there are not color modification (*figure 2, figure 3*).

We present several cases solved with Zirconia Implants.

In case of a patient who presented 2 deciduous canines and the ortopantomography proving a good high for implant (*figure 4, figure 5*).




Figure 1

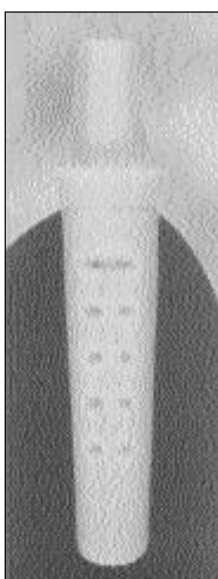

Figure 2

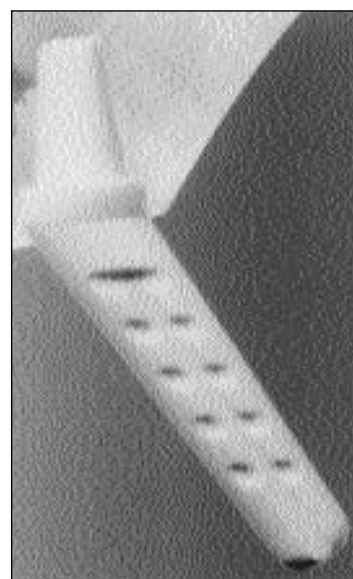


Figure 3

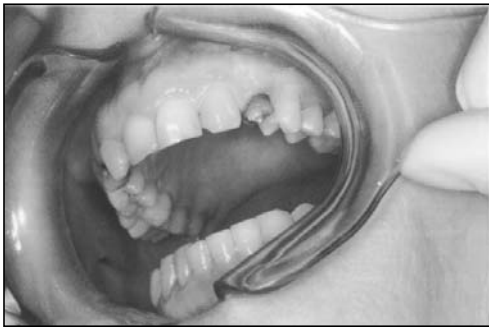

Figure 4

A vestibular flap is realized, without touching the papillae (figure 6).

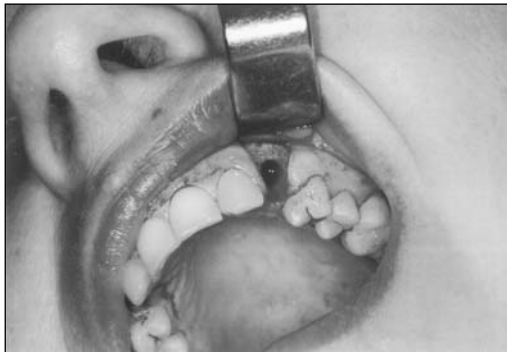

Figure 6

After drilling, the implant is inserted in its place, leaving 0,5 mm of the implant neck outside the bone, for obtaining a very good contour of soft tissues around the implant (figure 7 and figure 8).

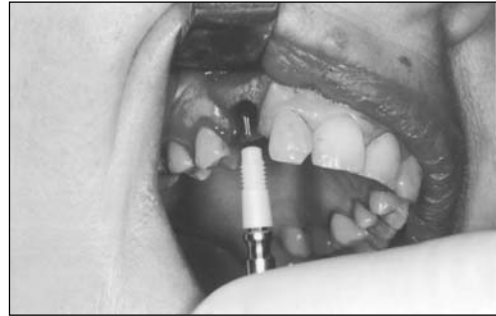

Figure 7

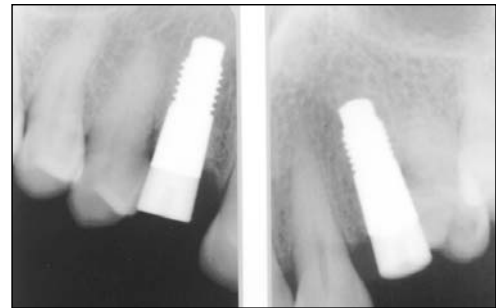


Figure 8

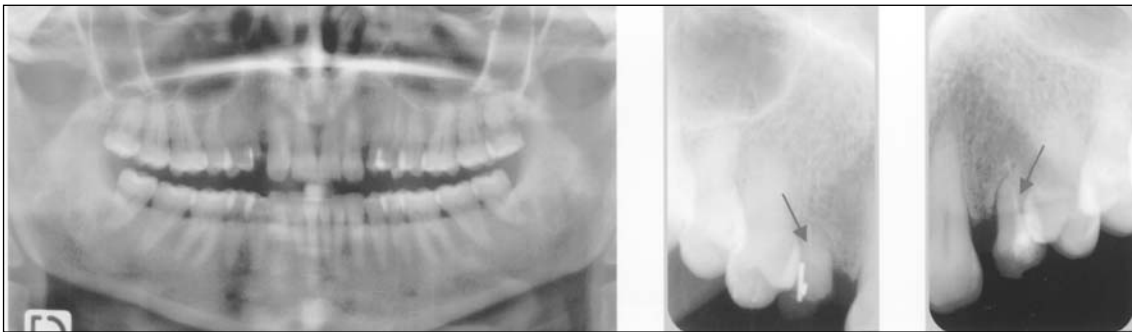


Figure 5

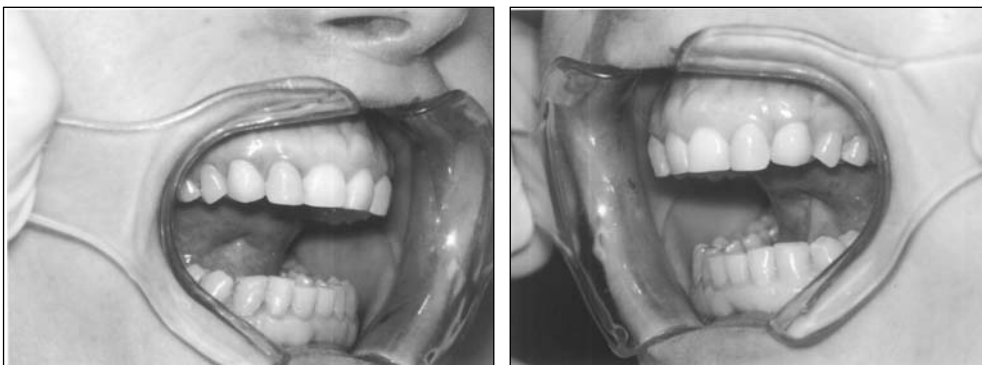


Figure 9

After a 6 weeks healing period, the prosthetic reconstruction is realized (figure 9).

The second clinical case

Is a case in which the one stage surgery was decided.

The monobloc Zirconia Implants were used, after inserting the implant up to the level where the neck diameter increases, the provisory crown is placed in the same day, for modeling the gingival contour (figure 10, figure 11).

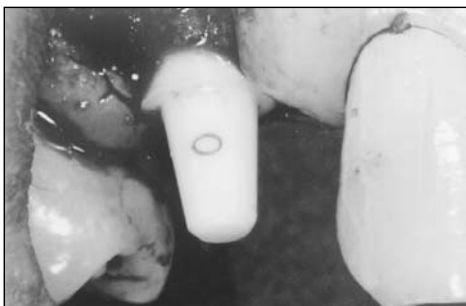


Figure 10

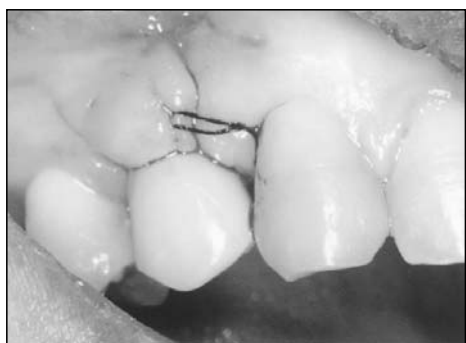

Figure 11

After a 6 weeks healing period, the cervical region could be modified using the same principles used in conventional prosthodontics, in order to obtain the best emergence of the crown (figure 12).

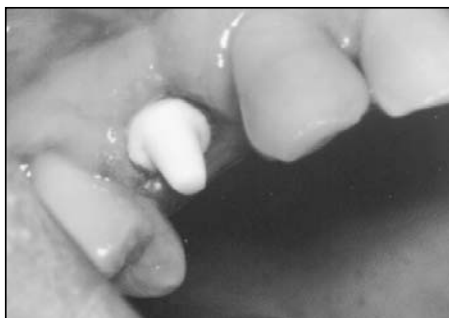

Figure 12

The final IN-CERAM crown will be cemented 8-10 weeks after insertion of implants (figure 13).

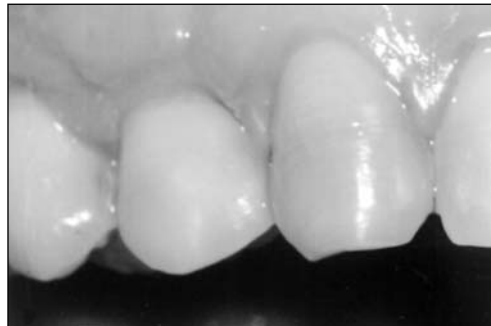

Figure 13

The third clinical case

The third clinical case presents a patient who lost the central incisor 11 in an accident. The patient received an implant monobloc which was prepared to achieve the best physiognomy and received the provisory crown (figure 14, figure 15).

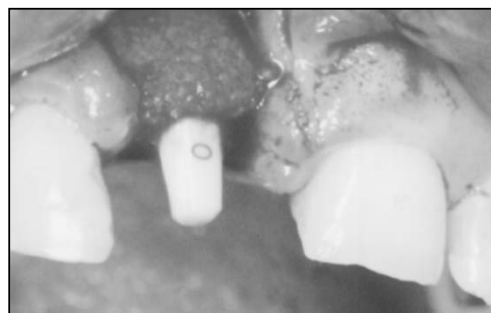

Figure 14

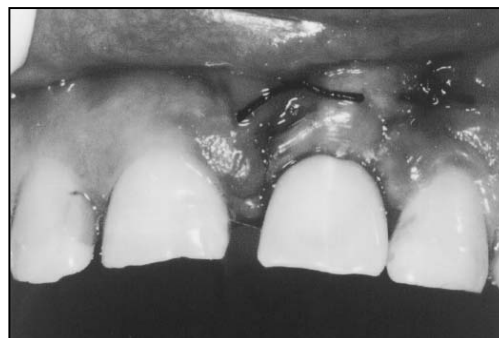

Figure 15

After 6 month gingival retraction has occurred, the neck of implant was visible. The gingival contour was prepared using a diamond

drill and the final ceramic crown was cemented (*figure 16 and figure 17*).

Conclusions

The "DIAMOND IMPLANTS" correspond to all criteria of mechanical resistance, biocompat-

ibility, viability, rapid healing, they belong to the future of Implantology, they permit us a rehabilitation using simple, viable methods which bring us close to methods used in conventional prosthodontics, for natural teeth.

It seems to prove the saying "DIAMANTS ARE FOR EVER".

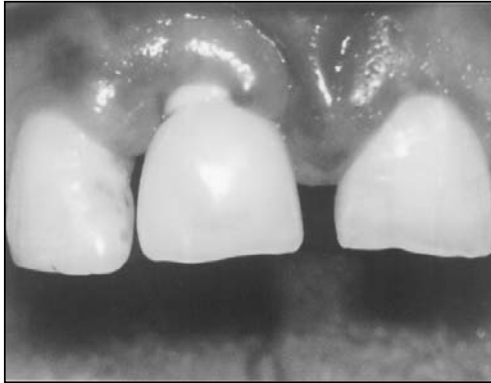

Figure 16

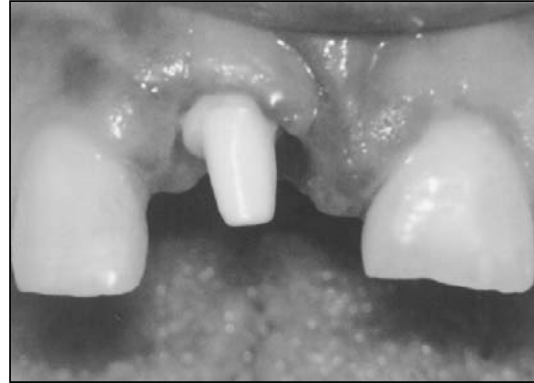


Figure 17

Correspondence to: Dr. Alain Clairet, Port van Gogh, 2, quai Aulagnier, 92600 Ansieres sur Seine, France.
E-mail: alainclairet@wanadoo.fr
Dr. Bogdan Vladila, Bucuresti, bogdanvladila@yahoo.com