

## Thermography- investigation method of diagnosis and treatment in temporomandibular joint territory

Daniela Gheorghiu<sup>1</sup>, Bogdan Gheorghiu<sup>2</sup>

### Summary

**OBJECTIVES.** The goal of this article is to accommodate dentists with the idea that thermography can offer a correct image of inflammation in oro-facial territory, especially about both temporomandibular joint. These images can be taken before and during the treatment or after the treatment was completed. Also, the material presents some solved cases with temporomandibular joint disorders, thermo grams registered before and after the prosthetic treatment.

**METHOD.** The method consists in receiving of infrared radiation emitted by any warm body, with temperature between 20-40 Celsius degrees. The device is called thermograph and is forecasted by a sensor, lens, a translate devise to a personal computer. The computer must be loaded with special software able to convert the received signal into a colored map. The patient must stay on a regular chair with a head device.

**RESULTS.** Obtained maps were read, printed and stored in a data base, then compared with standard maps. In patient treated thermograms have shown modified maps comparatively with pre-treatment situation.

**CONCLUSIONS.** Thermography is an alternative investigation in temporomandibular disorders diagnosis. The principle of this method is very simple, non- invasive, not expensive and offers reliable images on temporomandibular territory.

**Key-words:** thermography, thermograms, temporomandibular disorder, maps.

### INTRODUCTION

Thermography is a method wide used in internal medicine, but too little in dentistry medicine, in spite of easier and non- invasive realization. (1) Regularly, inflammations processes are not visible through traditional investigations methods, we can just guess it, grace to osseous aspect. Joint repositioning is not complete if we obtain an joint symmetry, bone regeneration or lack of clinical symptoms. It can be an inflammatory chronic hotbed, invisible for another clinical and para clinical assessments and who can break out later.(2) Conventional x- rays exposures are fasts, painless, cheap, but

show just structural changes in bones and teeth. Tomography shows slices through joint, with condilian position or changes in bone structures. Better informations can result if we use CT (computer tomography) or CAT- Scan about soft tissues, but RMN is the accurate technique for them. Other techniques are expensive, uncomfortable, requiring sophisticate equipment. Even so, these techniques not offer a “healing” image, lack of inflammation in soft and hard tissues. (3)

Any tissues sufferance is accompanied by for signs: *rubor, tumor, dolor, calor*. The last one can be measured today through thermography. Every warm bodies have

<sup>1</sup> dentistry specialist, master, Suceava

<sup>2</sup> dentistry specialist, master, Suceava

moving Brownian particles. They crush each other, resulting thermic energy, measured with thermometer or thermograph. More interactive movements it results more thermic energy.

## MATERIAL AND METHOD

The method consists in receiving of infrared radiation emitted by any warm body, with temperature between 20-40 Celsius degrees. The device is called thermograph and is forecasted by:

- a sensor which can receive infrared radiation in electromagnetic spectrum (e.g. 900- 10.000 nm);
- a mirrors system;
- lens;
- a translate image devise to a personal computer.

Thus, warm objects became well visible, in contrast with colder environment. Hence, this method is useful in military and security services, day and night. The computer must be loaded with special software able to convert the received signal into a colored map. The patient can stay on a regular chair with or without a head device. (1+2)

Thermogram maps can reveal data about: teeth, attached and free gingiva, alveolar mucosa, posterior side of soft palatus. There are two kind of thermograms: static and dynamic.

● static thermogram offers informations about:

- diagnosis of orofacial chronic pains;
- evaluation of temporomandibular disorders;
- helps in evaluation of alveolar inferior nerve deficit...(5+6)

● dynamic thermogram gives quantitative information about hemodynamic processes of thousands thermic digital images in affected areas, measured and stored in less than 3 minute.

Thermograms are related to the local, bilateral and distal gradient. There are two kind of images, too:

- isothermic images;
- hypothermic images;
- hiperthermic images. Fig 1.

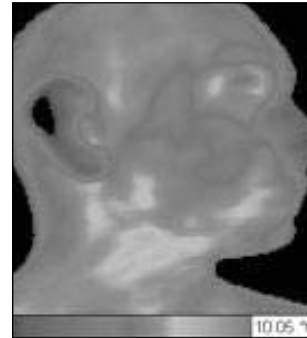


Fig 1.

Isothermic images appear coloured in green, warmer zone are yellow, hot areas appears red and cold areas are coloured in blue and black.

Normal thermograms of temporal region must be symmetrical, green. The external ear appears to be black, so the external conduct of ear.

We have examined 15 patients through clinical, x-rays and termographyc methods. Among these, we have selected three interesting cases and the results of investigation.

1. C.T., 45 years. The patient presented to the clinical and x-rays examination an multiple edentations, complicated by attritions, rotations, migrations of restants teeth, malocclusion second Angle Class with superior teeth and alveolar process in protrusion, lateral occlusion crashed. Panoramic radiography and tomography have been shown condilian displacement, the left one was in an anterior position, with articular space reduced. (7+8)

Thermography pre-treatment have been shown a warm, asymmetric, hyperthermic area on left temporomandibular joint and left maseter muscle; in addition, there is a hyperthermic (yellow) area to the apical area of right superior canine. Fig 1.1 and 1.2.

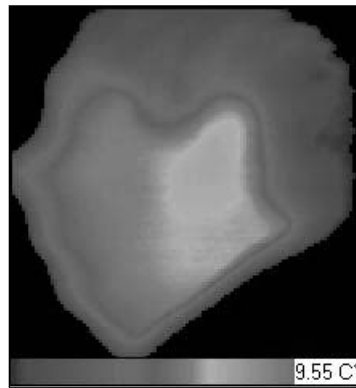



Fig 1.1 and 1.2

That indicates an increased inflammatory area in left temporomandibular joint, left masesterian hypertonia, apical reaction on superior right canine; inflammatory reaction on submandibular and latero- cervical lim-

fonodular ganglions.

Post- treatment thermogram shows isothermic areas in both temporomandibular joints, so the treatment was properly. Fig 1.3 and 1.4.

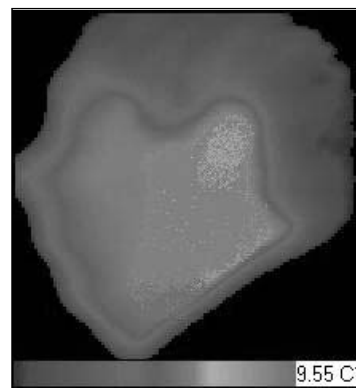
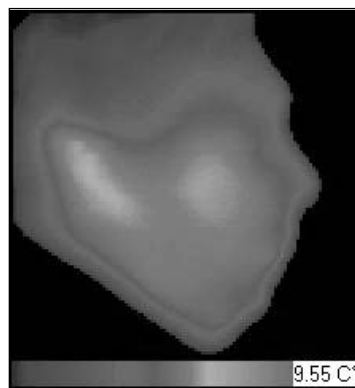


Fig 1.3 and 1.4

2. C.E., 42 years. Diagnosis consists in wide bimaxillary edentation, multiple decays, attritions, rotations, migrations of restants teeth, lateral occlusion crashed. Panoramic radiography and tomography have been shown condilian displacement, the right one was intruded and the left one was laterally displaced and extruded. Articular right space was reduced. (8)

Thermography taken pre-treatment has been shown a warm, asymmetric, hyperthermic area on left temporomandibular joint (?t°=0.54 °C), secondary: hyperthermic area

on nose, eyes and farinx area. Fig2.1 and 2.2. That indicates an an increased inflammatory area in left temporomandibular joint, inflammatory reaction on submandibular limfonodular ganglions. Otherwise, the patient presents an acute farinx and nose disease, troubles in ocular accommodation. After treatment, thermograms revealed isothermic areas in both temporomandibular joints, so lack of inflammation. Unfortunately, a faringian and nasal reaction persists. Fig. 2.3 and 2.4.

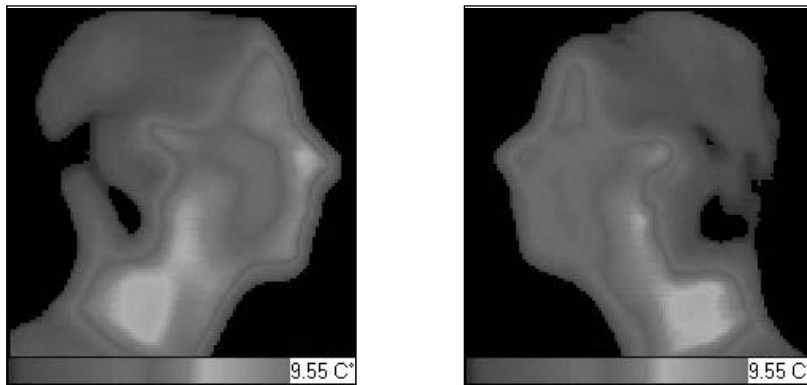


Fig. 2.3 and 2.4

3. O.G, 21 years have been shown to the clinical exam minor dental lesions, a malocclusion third class Angle, overjet 0, overbite 0, but the tomography revealed asymmetry in condylar anatomy, right condyle positioned to medial and anterior sides, just in occlusal position.

Thermography taken before treatment

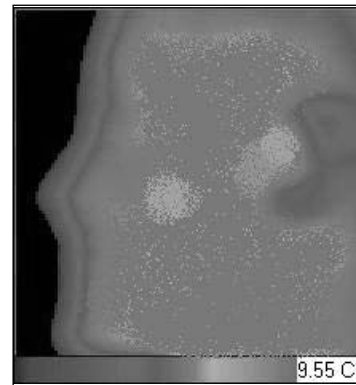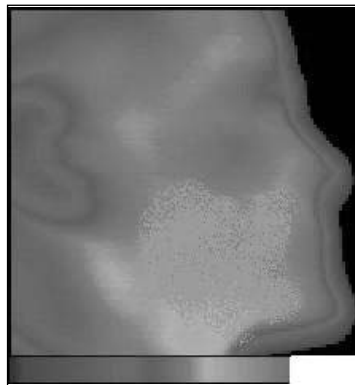


Fig.3.3 and 3.4

has been shown a warm, asymmetric, hyperthermic area on right temporomandibular joint, also in farinx and maxillary sinus areas. Fig.3.1 and 3.2. After treatment, the areas of both joints appear to be green, so without inflammation; secondary, the non-odontogenic sinusitis persists. Fig.3.3 and 3.4.

### DISCUSSIONS.

A thermogram can offer precise images for:

- diagnosis and dynamic changes in inflammatory processes within facial area and limfoganglionar regional reactions;
- diagnosis of temporomandibular disorders and bones and nerves disorders;
- articular pain in arthritis, osteoarthritis, reumathoid arthritis...
- muscular pains, hyper- or hypotonic reactions;
- monitoring endodontic treatments;

- tissues reactions to new dental materials;
- diagnosis and evolution of any kind of maxilo- facial inflammation;
- chronic and acute periodontitis;
- sinus disease;
- extended maxilo- facial infections;
- “warm” cancers in maxilo- facial territory;
- miofascial pain syndrome;
- nevralgia.

In examined patients, the thermograms pre- treatment revealed any thermal sign of inflammation, most of them localized in

TMJ territory, adjacent muscles, apical areas and limfoganglionar chain. After the treatment was ended, patients were re-examined by thermograph, and we found positive changes in thermal reactions. Thermograms show isothermic areas, coloured in green.

Advantages of thermography include:

- non-invasive technique;
- easy seating examination;
- minimal examination time (2-3 minute);
- non-expensive technique;
- obvious differences in color changes (gradient= 0,05°C).

There is a false result given by lipsticks, moisture mist and dermatological lesions.

In order to store thermograms, we can use many methods:

- printing on paper, Xerox paper or coated with a material that changes color on heating; this is the thermal printing;

- magnetic device (CD, Disc or computer database, archive).

## CONCLUSIONS

1. Thermography may be important in elaborating of a right diagnosis on an inflammatory reaction from maxilo-facial territory.

2. In dentistry, thermography can become important because of accurate measurement of regional temperature (0, 05°C differences).

3. "Warm", so inflammatory areas are obvious, strictly localized, and easy to read;

4. After-treatment thermograms can give important relations about the treatment methods and their efficiency.

5. Thermograms can be saved in a database, on compact disc or printed on a special or regular paper.

Acknowledgements. This paper was written as part of ours doctorates, referents: prof. dr. Vasile Burlui, Prof. Dr. Mircea Rusu

## BIBLIOGRAPHY

1. Application of thermography in dentistry—visualization of temperature distribution on oral tissues. *Komoriyama M, Nomoto R, Tanaka R, Hosoya N, Gomi K, Iino F, Yashima A, Takayama Y, Tsuruta M, Tokiwa H, Kawasaki K, Arai T, Hosoi T, Hirashita A, Hirano S.; Department of Dental Engineering, Tsurumi University School of Dental Medicine, 2-1-3 Tsurumi, Tsurumi-ku, Yokohama 230-8501, Japan. Dent Mater J. 2003 Dec;22(4):436-43.*
2. Thermology and facial telethermography: Part II. Current and future clinical applications in dentistry. *Gratt BM, Anbar M Section of Oral Radiology, UCLA School of Dentistry 90095-1668, USA. Reference: G.F. Carrera, MD, "Diagnostic Imaging of the Temporomandibular Joint," The TMJ Report 2(2): 4-6, May 1992.*
3. TMJ Trauma and Its Rehabilitation. *R. C. Schafer, DC, PhD, FICC, Manuscript Prepublication*

Copyright 1998 *Berkman EH: The Troublesome TMJ. ACA Journal of Chiropractic, June 1971.*

4. "Doctor, My Jaw Hurts." *Patient Care*, pp 108-136, **December 15, 1983.**

5. *A Clinical Outline of Temporomandibular Joint Diagnosis and Treatment.* Farrar WB, McCarty WL Jr, Montgomery, AL, **Normandie Publications, 1982.**

6. Hruby RJ: The Total Body Approach to the Osteopathic Management of Temporomandibular Joint Dysfunction. *Journal of the American Osteopathic Association*, **85(8):502-509.**

7. Kessler RM, Hertling D (eds): *Management of Common Musculoskeletal Disorders.* Philadelphia, Harper & Row, **1983**, pp 233-271, 533-537.

8. Smith SD: Vascular Analysis in Temporomandibular Orthopedics: Quantifying Blood Flow Related to Occlusal Dynamics. *Osteopathic Medicine*, pp 29-32, 35-41, **71, October 1980.**

\*\*\*

Correspondance to: Daniela Gheorghita, Dentistry Specialist, Master; Suceava, Str. Tipografieii, Nr4, Bl A5, Sca, Ap2, Tel 0744170331/0230210555, E-Mail: Dentalmed2004@Yahoo.Com