

Talon's Cusp in Fused Permanent Mandibular Incisors: Report of a Rare Case

Mridula G, Babita J, Jatinder Kaur D

Department of Pedodontics and Preventive Dentistry, Maulana Azad Institute of Dental Sciences, New Delhi-110002, India.

Abstract

Talon's cusp and Fusion are rare dental developmental anomaly affecting primary and permanent dentition. Fusion is common in primary dentition while Talon's cusp is common in maxillary teeth. The concomitant occurrences of Talon's cusp with fusion in permanent mandibular anterior teeth are extremely rare. As these developmental anomalies are associated with clinical problems including esthetic impairment, pain, dental caries and tooth crowding, a careful diagnosis and thoughtful treatment plan is necessary to prevent further progression of dental problems. This case report presents an unusual occurrence of Talon's cusp with fusion in permanent mandibular incisors. Based on clinical and radiographic findings importance of dental anomaly and awareness of dental problems are also discussed.

Key Words: Developmental dental anomaly, Fusion, Talon's cusp

Introduction

The developmental dental anomaly Talon's cusp was first described by Mitchell in 1892 [1] as a horn like process, curving from the base downward to the cutting edge on the lingual surface of a maxillary central incisor of a female patient [1,2]. This accessory cusp was named by Mellor and Ripa as Talon's cusp because of its resemblance in shape of eagle's talon [3]. It occurs more frequently in maxilla than mandible and maxillary anterior region has more prevalence as compared to posterior [4-6]. The permanent dentition is affected more as compared to the primary dentition, and the males being affected more than females [4-6]. Talon's cusp of anterior teeth is characterized by the presence of an accessory cusp like structure projecting from cingulum area of cemento-enamel junction [7]. Fusion is characterized by union of two or more hard tissues of two or more teeth by their dentin and pulp [8]. The co-occurrence of two developmental dental anomalies is rare [1]. Talon's cusp in fused permanent mandibular anterior teeth is a rare entity [1]. This case report presents a rare case of fusion in permanent left mandibular incisors with Talon's cusp.

Case Report

A 6 year-old male patient reported to the Department of Pedodontics and Preventive Dentistry with his mother, with a chief complaint of large, unsightly mandibular central incisor. Patient's medical and family history was noncontributory. There was no significant past Dental history and no history of orofacial trauma. On clinical examination the patient was apparently well and of normal physical development for his age. On extra oral examination, no clinical abnormality was found. On intra oral examination permanent mandibular left central incisor had a large crown with mammelons incisally (Figure 1). The tooth was two third erupted in oral cavity and rotated from its normal position (Figure 2). The permanent mandibular left central and lateral incisors were provisionally diagnosed to be fused as lateral incisors were not visible in the oral cavity. A pyramidal cusp-like projection resembling

a Talon's cusp was observed on the lingual surface of tooth (Figure 3).

An intraoral periapical (Figure 4) and mandibular occlusal radiographs (Figure 5) were taken which revealed fusion of teeth on the coronal aspect, and two separate roots in close apposition with each other. Both the radiographs revealed the fusion of crowns of the two teeth with two pulp chambers, two root canals with open apex and inverted "V" shaped

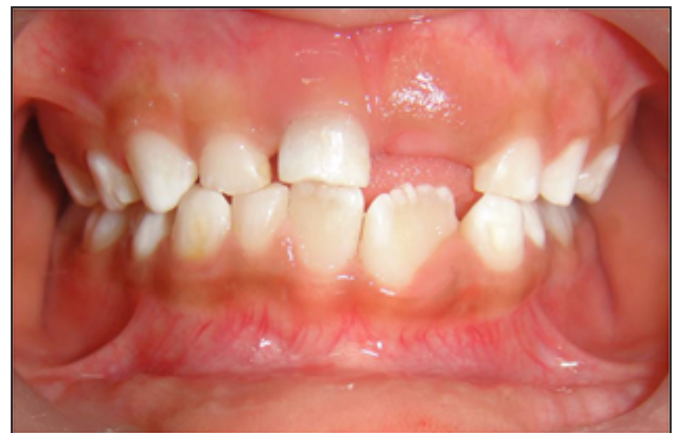

Figure 1. Front view showing large left mandibular central incisor.

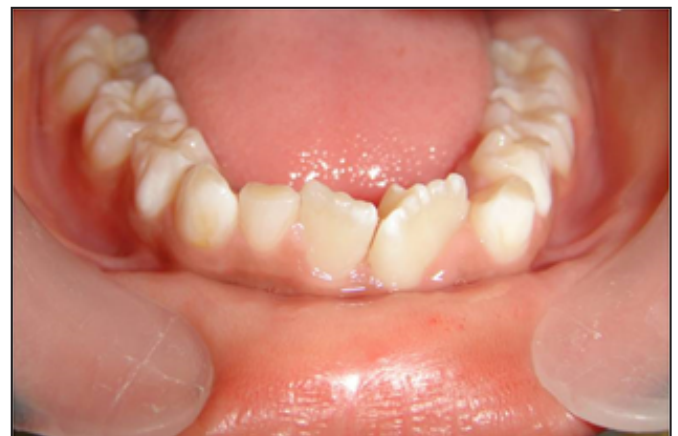

Figure 2. Front view showing fused left mandibular teeth with lingual talon cusp.

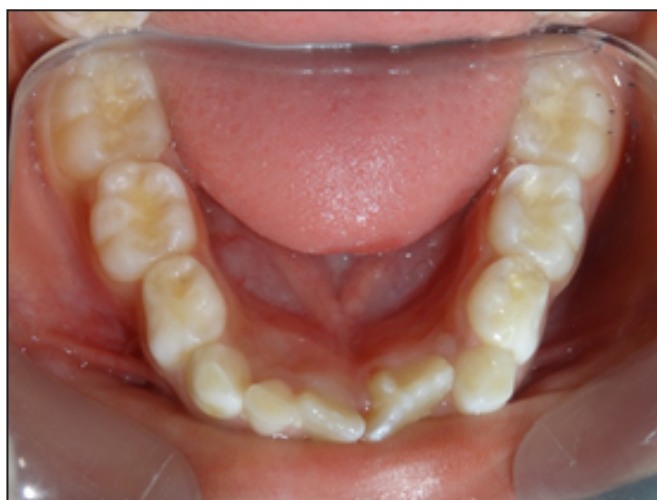

Figure 3. Occlusal view of Talon's cusp on fused left mandibular teeth.

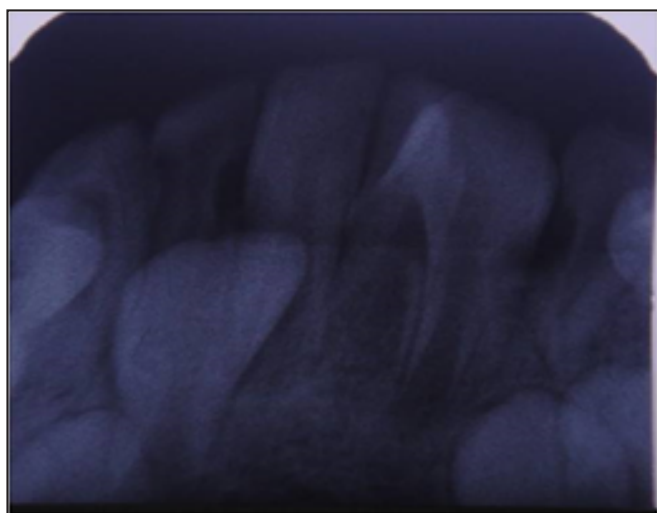


Figure 4. Intraoral Periapical radiograph showing fusion of crowns with two separate roots.

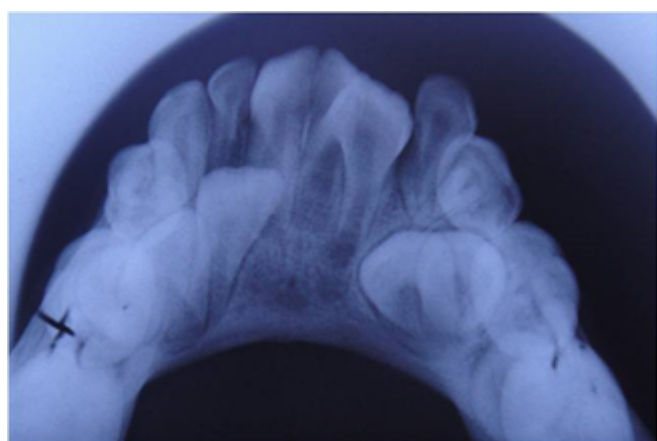


Figure 5. Mandibular occlusal view radiograph showing fusion of mandibular teeth with Talon's cusp.

radiopaque structure superimposed on affected crowns. The inverted "V" shape structure consisted of enamel; dentin with containing pulp chamber arising from the cingulum of teeth confirms the presence of a Talon's cusp.

Based on clinical and radiographic findings Talon's cusp in this case is categorized as Type 1 or True Talon according to Hattab et al classification. As the fused teeth were clinically asymptomatic, patient reported no associated problems with

the accessory cusp, so no active intervention was carried out. Patient was scheduled for periodic dental examination.

Discussion

Simultaneous occurrence of multiple dental abnormalities is relatively rare [1]. Talon's cusp is a relatively rare developmental anomaly of tooth shape that occurs as an additional cusp on the labial or lingual surface of primary or permanent anterior teeth [4] with prevalence ranging from 0.06% to 7.7% [7]. In literature, Talon's cusp are reported to be more frequent in the maxilla (92%) with 55% reported cases in lateral incisors, 32% in central incisors and 9% in canines [4,5]. The etiology of talon cusp is still unknown but it appeared that the genetic and environmental components had their influence on it [5,6]. Talon's cusp originates during the morpho- differentiation stage of tooth development. It may occur as a result of outward folding of inner enamel epithelial cells and transient focal hyperplasia of the peripheral cells of mesenchymal dental papilla [3-6,9]. Hattab et al. classified Talon's cusp into three types, namely true, semi- and trace Talon [7]. Type 1 or True talon is a morphologically well-delineated additional cusp that prominently projects from the palatal surface of a primary or permanent anterior tooth and extends to at least half the distance from the cemento-enamel junction to the incisal edge; Type 2 or Semi talon is an additional cusp of 1 mm or more that extends to less than half the distance from the cemento-enamel junction to the incisal edge and blends with the palatal surface or stands away from the crown; Type 3 or Trace talon is an enlarged or prominent cingulum with variations such as conical, bifid or tubercle-like [5,6]. In this present case Talon's cusp Type 1 was diagnosed.

Fusion indicates the union of discrete tooth germs [8] and the result of mutations during the odontogenesis [10,11]. Depending on the developmental stage, fusion may be complete, resulting in the formation of a wide tooth (crown and root) or incomplete, resulting in union only at the crown or root [12-15]. Shafer et al theorized that fusion is the result of specific pressure or physical force that results in direct contact of the developing two tooth germs. This intimate pressure causes necrosis of the intercellular tissues, allowing the close union of these two tooth germs [16]. The incidence of fusion reported 0.1% in the permanent dentition and 0.5% in the primary dentition [17] most commonly affected region is the primary mandibular anterior [18]. There is no difference reported in between both the sexes [19]. Talon cusps in mandibular anterior teeth with concomitant developmental anomalies are very rare [1]. In literature, only few previous case reports of Talon's cusp with fusion in the mandibular incisors are reported [20-22]. Ekambaram et al reported a case report of fusion in the mandibular permanent incisors with facial and lingual Talon cusps [20]. Dinesh et al. reported a case of fusion in mandibular permanent incisors with a lingual talon cusp associated with hypodontia of an adjacent tooth. Thirumalaisamy et al. [23] reported Talon's cusp on fused permanent mandibular left central and lateral incisors. Prabhakar et al. reported bilateral fusion of permanent mandibular incisors with Talon's [24]. Cho S reported a few cases of Talon cusps in permanent mandibular anterior teeth with fusion [25]. The case presented here showed typical

clinical characteristics of fusion between central and lateral incisors. On clinical examination there is fusion of the crowns of two teeth, as the lateral incisor is not seen clinically in the oral cavity. On radiographic examination, there is incomplete fusion of the crowns of two teeth, as two pulp chambers, two root canals were present. At the fusion of two teeth there is exuberation of radio opacity due to proliferation of ameloblasts. There is no pulp tissue within the Talon's cusp. Talon's cusp reported was characterized as Type I or True talon.

Fused teeth with Talon's cusp are associated with clinical problems like malocclusion, attrition, compromised esthetics, occlusal interference and accidental cusp fracture, irritation of tongue, displacement of teeth, breast feeding problems and caries susceptibility because of deep developmental grooves [5]. Presence of Talon's cusp can further exaggerate the above mentioned situations [11]. Various treatment modalities for mandibular incisors include prophylactic placement of sealants in the developmental groove, recontouring, periodic reduction of Talon's cusp followed by topical fluoride application, and endodontic treatment in cases which

results in pulp exposure [5,7], followed by their separation and shaping out in required forms. Sharp edges can also be smoothed easily after endodontic procedures. If any occlusal interferences are encountered the teeth can be ground in two to three appointments [11]. Careful early diagnosis and prompt management of Talon's cusp is important to prevent exaggeration of dental problem [5]. On radiographic examination, it is difficult to trace pulpal configuration inside the talon cusp because the cusp is superimposed over the affected tooth. In the case presented here, as there were no associated problems or symptoms with involved teeth, no active treatment of the Talon's cusps was carried out. If esthetic is major concern then root canal treatment followed by complete crown will indicated in this case.

Conclusion

Talon's cusps in mandibular anterior teeth with fusion are very rare. A careful early diagnosis and thoughtful management of Talon's cusp is important to prevent exaggeration of dental problem. Further a long term follow up is required in these cases for future management.

References

- Gunduz K, Acikgoz A. An unusual case of Talon cusp on a geminated tooth. *Brazilian Dental Journal*. 2006; **17**: 343-346.
- Mitchell WH. Case report. *Dental Cosmos*. 1892; **34**: 10368.
- Mellor JK, Ripa LW. Talon cusp: A clinically significant anomaly. *Oral Surgery Oral Medicine Oral Pathology*. 1970; **29**: 225-228
- Davis PJ, Brook AH. The presentation of talon cusp: Diagnosis, clinical features, associations and possible etiology. *British Dental Journal*. 1986; **160**: 84-88.
- Hattab FN, Yassin OM, Al-Nimri KS. Talon cusp-Clinical significance and management: Case reports. *Quintessence International*. 1995; **26**:115-120.
- Hattab FN, Yassin OM, Al-Nimri KS. Talon cusp in permanent dentition associated with other dental anomalies: review of literature and reports of seven cases. *ASDC Journal of Dentistry for Children*. 1996; **63**: 368-376.
- Chawla HS, Tewari A, Gopalkrishan NS. Talon cusp-prevalence study. *Journal of Indian Society of Pedodontics and Preventive Dentistry*. 1983; **1**: 28-34.
- Neville BW, Damm DD, Allen CM, Bouquot JE (Editors) *Oral and Maxillofacial Pathology*. Philadelphia: WB Saunders. 2005; pp.74-75.
- Siraci E, Gungor HC, Cehreli ZC. Dens invaginatus and talon cusp co-occurring in a mandibular central incisor: A case report. *Journal of Dentistry for Children*. 2008; **75**: 177-180.
- Nagaveni NB, Umashankara KV, Vidyullatha BG, Sreedevi S, Radhika NB. Permanent mandibular incisor with multiple anomalies-report of a rare clinical case. *Brazilian Dental Journal*. 2011; **22**: 346-350.
- Killian CM, Croll TP. Dental twinning anomalies; the nomenclature enigma. *Quintessence International*. 1990; **21**: 571-576.
- Varoli OJ. Radiologia. In: Guedes-Pinto AC (Editor) *Odontopedia Tria. Sao Paulo' Livraria Santos*. 1988; pp. 3305-3393.
- Atkins CO, Mourino AP. Management of a supernumerary tooth fused to a permanent maxillary central incisor. *Oral Surgery, Oral Medicine, Oral Pathology*. 1986; **61**: 146-148.
- Puy L, Pizarro C, Navarro F. Double teeth: Case reports. *Journal of Children Pediatric Dentistry*. 1991; **15**:120-124.
- Tommasi AF. Diagnóstico em Patologia Bteial. Sao Paulo: Artes Medicas. 1985; pp. 85-97.
- Shafer WG, Mine MK, Levy BM (Editors) *Tratado de Patologia Bucal (2nd edn.)* Rio do Janeiro: Discos CBS. 1984; pp. 295.
- Kelly JR. Geminatio, fusion or both. *Oral Surgery, Oral Medicine, Oral Pathology*. 1987; **45**: 326-327.
- Hassan FS, Al-Sarraj F. Fusion of primary teeth a case report. *Quintessence International*. 1989; **20**: 149-152.
- Jarvinen S, Lehtinen L, O Reilly PMR. Structural and radiographic evaluation of four cases of tooth fusion. *Australian Dental Journal*. 1990; **35**: 226-229.
- Ekambaram M, Yiu CKY, King NM. An unusual case of double teeth with facial and lingual talon cusps. *Oral Surgery, Oral Medicine, Oral Pathology, Oral Radiology, and Endodontics*. 2008; **105**: 63-67.
- Li RW. Clinical variants in tooth number and crown form: A report of bilateral double teeth associated with a talon cusp. *Dental Update*. 2002; **29**: 403-408.
- Rao DB, Hegde S. A talon cusp on fused teeth associated with hypodontia: Report of a unique case. *European Journal of Dentistry*. 2010; **4**: 75-80.
- Thirumalaisamy E, Baskaran P, Jeyanthi K, Kumar S. Talon cusp in fused teeth: Rare concomitant occurrence. *Journal of Oral Maxillofacial Pathology*. 2012; **16**: 411-413.
- Prabhakar AS, Kaur T, Nadig B. Bilateral fusion of permanent mandibular incisors with Talon's cusp: A rare case report. *Journal of Oral and Maxillofacial Pathology*. 2009; **13**: 93-96.
- Cho SY. Talon cusps in mandibular incisors: Report of eight rare cases. *Journal of Indian Society of Pedodontics and Preventive Dentistry*. 2014; **32**: 185-188.