

# Sinus Lifting in the Presence of Pseudocyst: Case Series

Cagri Delilbasi, Gokhan Gurler, Ilker Burgaz

Department of Oral and Maxillofacial Surgery, School of Dentistry, İstanbul Medipol University, Atatürk Bulvarı No:27, 34083 Unkapani, İstanbul, Turkey.

## Abstract

Direct sinus lifting is a commonly performed procedure to install implants in the atrophic posterior maxilla. Anatomical variations and pathologies in the maxillary sinus may cause failure and complications, thus decrease success rate. Here, clinical documentation of seven patients who underwent direct sinus lifting and literature review were presented. Sinus lifting can be safely performed in the presence of antral pseudocyst. One should pay attention to decrease intraoperative (overgrafting the sinus, leakage of cyst content) complications and postoperative follow-up is mandatory for the development of maxillary sinusitis.

*Key Words: Sinus lifting, Pseudocyst, Maxillary sinusitis, Sinus floor augmentation*

## Introduction

Implant placement in the posterior maxilla is more challenging than the other parts of the jaws due to quantity and quality of the bone. Sinus lifting has been commonly used to insert implant in the posterior maxilla in case of alveolar bone deficiency [1-3]. Direct (lateral) and indirect (crestal) techniques have been described for sinus lifting of which can be preferred due to residual alveolar bone height [4,5-7]. Regardless of the technique used, risk assessment must be considered preoperatively to reduce or to prevent intraoperative and postoperative complications. Maxillary sinus cysts are mainly classified as; mucocèles, retention cysts and pseudocysts [4,6-9]. Mucocèles are defined as lesions that develop from extravasations of mucous into the surrounding soft tissues due to trauma or obstruction of salivary flow. They have potential to the destroy bone and expand to adjacent soft tissues [10,11]. Retention cysts are mucoid-filled cysts that develop when seromucous glands of the sinus mucosa are obstructed. These cysts are relatively small and cannot be clearly seen on radiographs [9,12].

Pseudocysts have inflammatory origin and result from accumulation within the sinus membrane. They appear as dome-shaped, sessile lesion and lack an epithelial lining [6,13,14].

Lesions including mucocèles, retention cysts, and pseudocysts located at the floor of the maxillary sinus may obstacle the sinus lifting procedure. Maxillary sinus infection and pathologies may increase the risk of surgical failure; therefore, proper patient selection, history of sinusitis or sinus operation comes into prominence for the success of sinus lifting procedure [15]. In this article, sinus lifting procedure in patients with antral pseudocyst as well as literature review were presented.

## Clinical Presentation and Intervention

Seven patients (5 men and 2 women) with age range of 29-77 years (mean age 49.1 years) requiring implant therapy for the maxillary posterior region at İstanbul Medipol University School of Dentistry Department of Oral and Maxillofacial Surgery were presented. Details of the patients were shown

in *Table 1*. Panoramic radiographic examination revealed insufficient alveolar bone height for the placement of implants and a dome-shaped, faintly radiopaque lesion suggestive of an antral pseudocyst was observed in the base of maxillary sinus. Cone Beam Computed Tomography (CBCT) was taken from all patients to evaluate the maxillary sinus and cystic lesion. Direct sinus lifting was indicated due to atrophy of the alveolar ridge and pneumatization of the maxillary sinus. We performed direct sinus lifting when the residual alveolar bone height was less than 7 mm. The height of the residual alveolar ridge ranged between 3.8 mm to 6.8 mm with a mean height of 4.6 mm.

Medical history of the patients was uneventful and did not impede with the surgical procedure. Two-stage lateral approach was performed in all cases. After raising a mucoperiosteal flap, osteotomy was performed with either piezosurgery device or rotative diamond burs (with copious sterile saline), osteotomes and mallets.

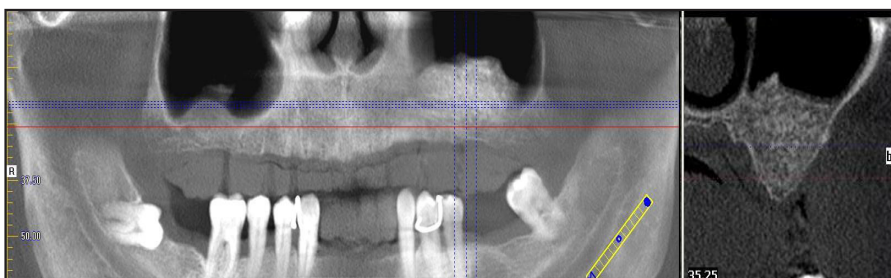
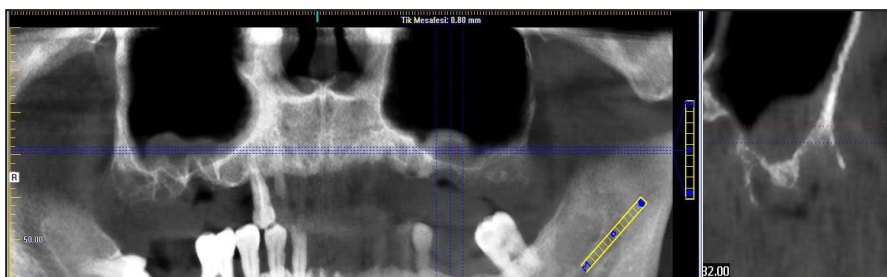
Sinus membrane elevation was performed with either piezosurgery tips or direct sinus elevators. The bony wall was gently pushed inside the sinus cavity to form the roof of the graft site. The occurrence of membrane perforation was noted. After completing sinus membrane elevation, allogeneous freeze dried corticocancellous bone chips (Maxxeus, Community Tissue Services, OH, USA) were used for grafting. Bony sinus window was covered with a resorbable collagen membrane (Collagene AT®, Sistema AT, Padova Italy). Mucoperiosteal flaps were primarily closed with 3/0 silk suture. All the patients were prescribed 875 mg amoxicillin + 125 mg clavulanic acid combination twice daily for 5 days and 500 mg paracetamol twice daily, 0.2% chlorhexidine mouth rinse starting from the next day of the surgery twice daily for 15 days. Sutures were removed after one week. Patient samples were shown in *Figures 1A-1C*, and *Figures 2A-2C*.

Membrane perforation occurred in one patient during the elevation of the membrane. Perforation was closed with a resorbable collagen membrane and the operation was carried on. In one patient, pseudocyst disappeared spontaneously, which was detected on postoperative radiographs. (*Figures 1B and 1C*). Membrane perforation and leakage of cyst content was not noticed during surgery in this patient. Control

**Table 1.** Details of the patients who were performed direct sinus lifting in the presence of antral pseudocyst.

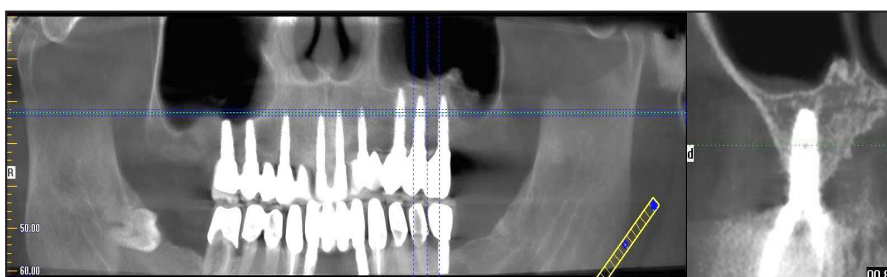
Patient no	Age	Gender	Cyst size LxW (mm)	Preoperative symptoms	Intraoperative complications	Postoperative complications	# Implants placed	# implant failure	Follow-up
1	41	M	9.26 x 11.76	-		Wound dehiscence	3	-	1.5 years
2	43	F	12.43 x 16.80	-	-		3	-	1 year
3	46	M	8.8 x 11.40	-	Membrane perforation	-	2	-	2 years
4	77	F	10 x 8.4	-	-	-	3	-	1.5 years
5	40	M	10.5 x 12	-	-	-	3	-	2 years
6	68	M	10 x 13	-	-	-	2	-	1.5 years
7	29	M	15.03 x 18.42	-	-	-	3	-	1 year

**Figure 1A.** Preoperative panoramic and coronal views of the pseudocyst in the left maxillary sinus (arrow) (patient no:5).



**Figure 1B.** Appearance after sinus lifting. Note the complete resolution of the pseudocyst.

**Figure 1C.** Radiographic appearance after implant insertion.



CBCT was taken from the patients before implant insertion. All the implants were inserted 6 months postoperatively and osseointegrated successfully. No sign or symptom of postoperative sinusitis developed in any of the patients.

Literature search was conducted online using PubMed ([www.ncbi.nlm.nih.gov](http://www.ncbi.nlm.nih.gov)) and Cochrane Library ([www.thecochranelibrary.com](http://www.thecochranelibrary.com)). Published articles until the year 2014, those in the English language, and case reports as well as clinical trials were included. Key words; sinus lifting, pseudocyst, maxillary sinusitis, sinus floor augmentation were given as search terms. Summary of the relevant literature was given in *Table 2*.

### Discussion and Literature Review

Direct sinus lifting has some complications such as membrane perforation, obstruction of maxillary ostium, bleeding, acute or chronic sinusitis, graft loss and implant failure. Ostium in patients with a pseudocyst may be blocked by overfilling the sinus cavity with bone graft during augmentation [1-3,15].

Thorough history taking and radiographic examination are mandatory for detection and differential diagnosis of sinus pathology. Pseudocysts can be differentiated from retention cysts and mucoceles. Retention cysts are generally located around the ostium as seromucinous glands are normally found around this area, whereas pseudocysts are located on the floor of sinus cavity. It is hard to distinguish retention cysts on radiographs due to their small size; however, pseudocysts vary in size from a small dome-shaped lesion to a very big lesion that could completely fill the maxillary sinus [6,9,10].

Maxillary sinus pseudocysts can be visualized on routine conventional radiographs but detailed evaluation can be managed by using plain CT, cone beam CT and MRI [10,12,14]. Pseudocysts are the pathologies usually found in routine radiographies which are recognized with dome-shaped or cyst like opacity in the maxillary sinus [8]. The prevalence is reported 1-10% on panoramic radiographs, 12% on CT and 21% on MRI [5,13,14]. We routinely use CBCT before sinus lifting since it provides more accurate diagnosis for

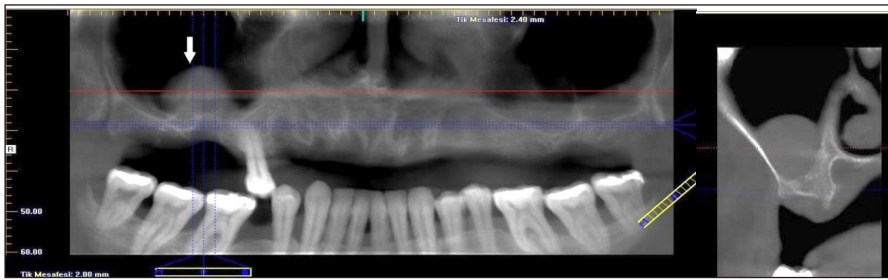


Figure 2A. Preoperative panoramic and coronal views of the pseudocyst in the right maxillary sinus (arrow) (patient no: 2).

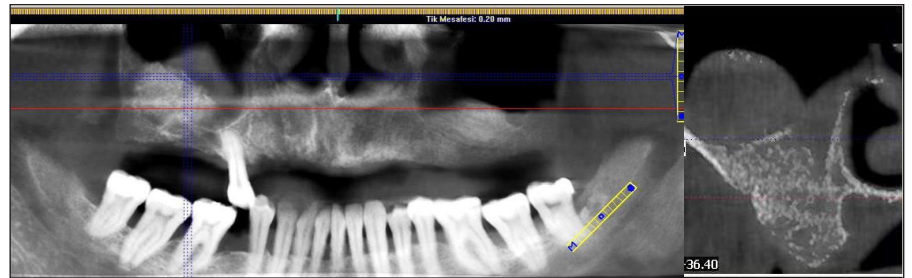


Figure 2B. Appearance after sinus lifting.

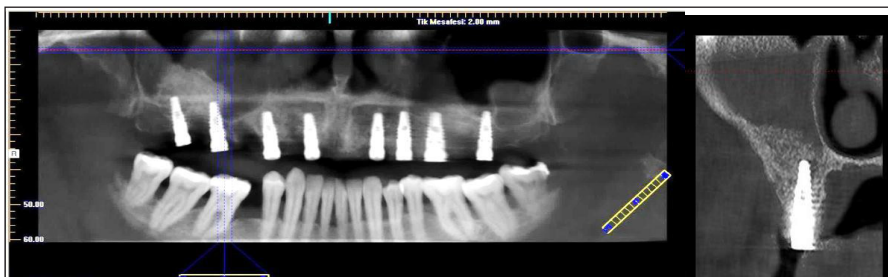


Figure 2C. Radiographic appearance after implant insertion.

Table 2. Summary of the literature review.

Authors, publication year	# patients	Sinus lifting Technique	Preoperative symptoms	Intraoperative complications	Postoperative complications	# Implants placed	#implant failure	Follow-up
Mardinger et al., 2007	8	Lateral	2/8 (sinusitis)	2/8 (fluid leakage and perforation)	1/8 (acute sinusitis)	24	1	20 months
Kara et al., 2010	2	Lateral	None	None	1/2 (infection)	NM , 2	None	7 and 10 months
Tang et al., 2011	1	Lateral	None	None	None		None	1 year
Celebi et al., 2011	4	2 Lateral, 2 crestal	None	None	None	4	None	6 and 8 months
Cortes et al., 2012	1	Lateral	None	None	None	6	None	1 year
Kara et al, 2012	29	17 lateral 12 crestal	3/29	1/17	2/17 (infection) 1/12 (infection)	31 17	None	14.3 months 18.5 months

NM: Not mentioned in the text

the detection of anatomical variations and pathologies in the sinus.

Previously, presence of an antral cyst was considered to be an absolute contraindication of sinus lifting procedure and sinus surgery was recommended to remove the cystic lesion. This resulted in additional surgical intervention for the patient as well as time loss as the sinus lifting could be performed at least 6 months following sinus surgery. Zicardi and Betts [15] suggested removal of the cyst before sinus lifting; however, recent reports are in favor of performing direct and indirect sinus lifting in the presence of pseudocyst and even large pseudocysts [3,6,14]. Mardinger et al. [14] reported sinus floor augmentation in 129 patients having antral cyst of whom 6 developed postoperative sinusitis. Infection was medically treated and no implant failure was observed. They also suggested that perforation of the sinus membrane in presence of an antral cyst is rare because of the thick mucosal lining.

Kara et al. [4] reported two cases having large pseudocysts that have undergone direct sinus lifting. They concluded that even though antral pseudocysts are not a contraindication for sinus augmentation, surgeons may face complications particularly if the lesions are large. Tang et al. [13] suggested that the treatment is unnecessary unless there is significant expansion through the sinus with clinical symptoms. Celebi et al. [6] reported four patients who have undergone either indirect or direct sinus lifting. No complications were encountered during the follow-up period and all inserted implants osseointegrated successfully. In another study, Kara et al. [5] performed 32 direct and indirect sinus lifting in 29 patients with antral pseudocysts. No sinus membrane perforation occurred in any patients and only two patients in the direct lifting group and one patient in the indirect lifting group developed acute sinusitis which could be managed medically. We did not encounter any postoperative maxillary sinusitis.



The most challenging complication of sinus lifting is the development of postoperative sinusitis and graft infection. The incidence of sinusitis is reported 3%-20% in previously healthy sinuses [14]. The presence of an antral cyst reduces the size of the maxillary antrum. This may further lead to decrease in the size of antrum due to sinus mucosa elevation which may result in blockage of the ostium and development of sinusitis. If the postoperative sinusitis is due to mucosal edema, it is transient and can be easily managed by appropriate medical therapy. Content of the pseudocyst may leak into the graft area which may cause graft infection and failure [14].

## References

1. Raja SV. Management of the posterior maxilla with sinus lift: Review of techniques. *Journal of Oral and Maxillofacial Surgery*. 2009; **67**: 1730-1734.
2. Esposito M, Felice P, Worthington HV. Interventions for replacing missing teeth: Augmentation procedures of the maxillary sinus. *Cochrane Database of Systematic Reviews*. 2010; **13**: CD008397.
3. Pjetursson BE, Tan WC, Zwahlen M. A systematic review of the success of sinus floor elevation and survival of implants inserted in combination with sinus floor elevation. *Journal of Clinical Periodontology*. 2008; **35**: 216-240.
4. Kara IM, Küçük D, Polat S. Experience of maxillary sinus floor augmentation in the presence of antral pseudocysts. *Journal of Oral & Maxillofacial Surgery*. 2010; **68**: 1646-1650.
5. Kara MI, Kirmali O, Ay S. Clinical evaluation of lateral and osteotome techniques for sinus floor elevation in the presence of an antral pseudocyst. *International Journal of Oral & Maxillofacial Implants*. 2012; **27**: 1205-1210.
6. Celebi N, Gonen ZB, Kilic E. Maxillary sinus floor augmentation in patients with maxillary sinus pseudocyst: case report. *Oral Surgery, Oral Medicine, Oral Pathology, Oral Radiology, and Endodontics*. 2011; **112**: 97-102.
7. Cortes AR, Corrêa L, Arita ES. Evaluation of a maxillary sinus floor augmentation in the presence of a large antral pseudocyst. *Journal of Craniofacial Surgery*. 2012; **23**: 535-537.
8. Lin Y, Hu X, Metzmacher AR. Maxillary sinus augmentation following removal of a maxillary sinus pseudocyst after a shortened healing period. *Journal of Oral & Maxillofacial Surgery*. 2010; **68**: 2856-2860.
9. Gardner DG. Pseudocysts and retention cysts of the maxillary sinus. *Oral Surgery, Oral Medicine, Oral Pathology*. 1984; **58**: 561-567.
10. Garg AK, Mugnolo GM, Sassen H. Maxillary antral mucocele and its relevance for maxillary sinus augmentation grafting: A case report. *International Journal of Oral & Maxillofacial Implants*. 2000; **15**: 287-290.
11. Perfetti G, Rossi F, Massei G. Sinus augmentation procedure of the jaw sinus in patients with mucocele. *International Journal of Immunopathology and Pharmacology*. 2008; **21**: 243-246.
12. Donizeth-Rodrigues C, Fonseca-Da Silveira M, Gonçalves-De Alencar AH. Three-dimensional images contribute to the diagnosis of mucous retention cyst in maxillary sinus. *Medicina Oral, Patología Oral y Cirugía Bucal*. 2013; **18**: 151-157.
13. Tang ZH, Wu MJ, Xu WH. Implants placed simultaneously with maxillary sinus floor augmentations in the presence of antral pseudocysts: A case report. *International Journal of Oral & Maxillofacial Surgery*. 2011; **40**: 998-1001.
14. Mardinger O, Manor I, Mijiritsky E. Maxillary sinus augmentation in the presence of antral pseudocyst: A clinical approach. *Oral Surgery, Oral Medicine, Oral Pathology, Oral Radiology, and Endodontics*. 2007; **103**: 180-184.
15. Ziccardi VB, Betts NJ. Complications of maxillary sinus augmentation in Jensen OT: The sinus bone graft. Carol stream, IL: *Quintessence Publishing*. 1999: pp. 201.