

# Root-Supported Overdentures Associated with Temporary Immediate Prostheses- A Case-report

Batista Victor Eduardo de Souza<sup>1</sup>, Almeida Daniel Augusto de Faria<sup>2</sup>, Santiago Junior Joel Ferreira<sup>2</sup>, Verri Ana Caroline Gonçalves<sup>2</sup>, Pellizzer Eduardo Piza<sup>3</sup>, Verri FellippoRamos<sup>4</sup>

<sup>1</sup>MSc Student, DDS. Aracatuba Dental School, UNESP – Univ Estadual Paulista, campus of Aracatuba, Department of Dental Materials and Prosthodontics, Sao Paulo, Brazil. <sup>2</sup>PhD Student, MSc, DDS. Aracatuba Dental School, UNESP – Univ Estadual Paulista. Campus of Aracatuba, Department of Dental Materials and Prosthodontics, Sao Paulo, Brazil. <sup>3</sup>Adjunct Professor, PhD, MSc, DDS. Aracatuba Dental School, UNESP-UnivEstadualPaulista, campus of Aracatuba, Department of Dental Materials and Prosthodontics, Sao Paulo, Brazil. <sup>4</sup>Assistant Professor, Department of Dental Materials and Prosthodontics, UNESP – Univ Estadual Paulista, Aracatuba, São Paulo, Brazil. José Bonifácio St, 1193, Aracatuba, São Paulo 16015-050, Brazil.

## Abstract

Complete denture fabrication can be a treatment challenge for many dentists, especially when the patient has remaining teeth. So, planning for use of clinical alternatives to improve the treatment prognosis and to enable greater comfort to patient must be considered. This case report describes the use of remaining roots to aid in the stability, support and retention of root-supported overdentures. Thus, immediate prostheses were planned for temporary rehabilitation prior to definitive overdentures. The aim of this study was to demonstrate the planning of root-supported overdentures attached with a ball system for retention associated with immediate dentures between the periods of preparation to fabrication of the definitive overdentures. The proposed treatment met the patient's needs such as being able to carry on normal activities during the sequencing of procedures to be performed over a period of time. The treatment had longevity with patient's knowledge about the necessity of oral hygiene and periodic controls.

*Key Words: Overdenture, Denture Semi- precision Attachment, Planning Techniques, Denture Complete Immediate*

## Introduction

The loss of teeth is generally associated with esthetic, functional, psychological and social impairment of the individual's life which may have a high impact of the patient's self-esteem and health [1,2]. Periodontal disease and dental caries are indicated as main causes for the loss of teeth and are associated with cultural and social factors such as financial sources, educational level and the access to health services [3,4].

In situations where extraction of the remaining teeth becomes necessary, the patient may feel embarrassed with social, psychological and esthetic factors. A method to minimize these problems is the use of immediate dentures made before dental extraction/preparation to be inserted after the surgical/prosthetic procedure [5,6]. In regards to the rehabilitation alternatives such as the use of dental implants, fixed prosthesis, removable partial or complete dentures, the overdenture rehabilitation is a viable and simple alternative and has been demonstrated to be efficient in these clinical situations [7]. Root-supported overdentures have been fabricated to correct periodontal and/or occlusal collapse. Some teeth are maintained to support and/or retain the prosthesis and therefore, maximizing prosthesis stability, besides preserving proprioception of the periodontal ligament and reducing bone loss [8-10].

Another important factor is the retention system choice. Among them the most used are: bar and clip, ball and O'ring, ERA or magnetic attachments. Usually, the choice is determined according to number, distance and location of the remaining natural teeth [11,12] or according to some clinical individual experience.

In some situations, the dissatisfaction of the patient using conventional complete dentures is observed because of the instability of the prostheses. This instability is generated by prostheses movement over the soft tissue mainly in the mandibular arch. Thus, the preservation of roots are an effective way to improve prosthesis support and can be associated or not with retention systems [8]. The aim of this clinical case report was to present an oral rehabilitation of maxillary and mandibular root-supported overdentures using a ball/o'ring system associated with fabrication of immediate dentures prior to definitive dentures fabrication.

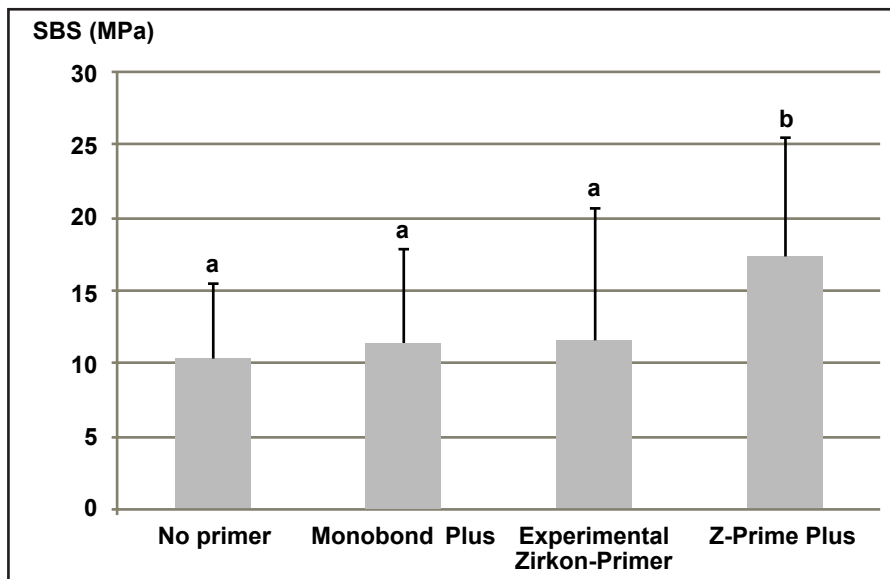
## Case Report

### Initial condition and surgical/prosthetic planning

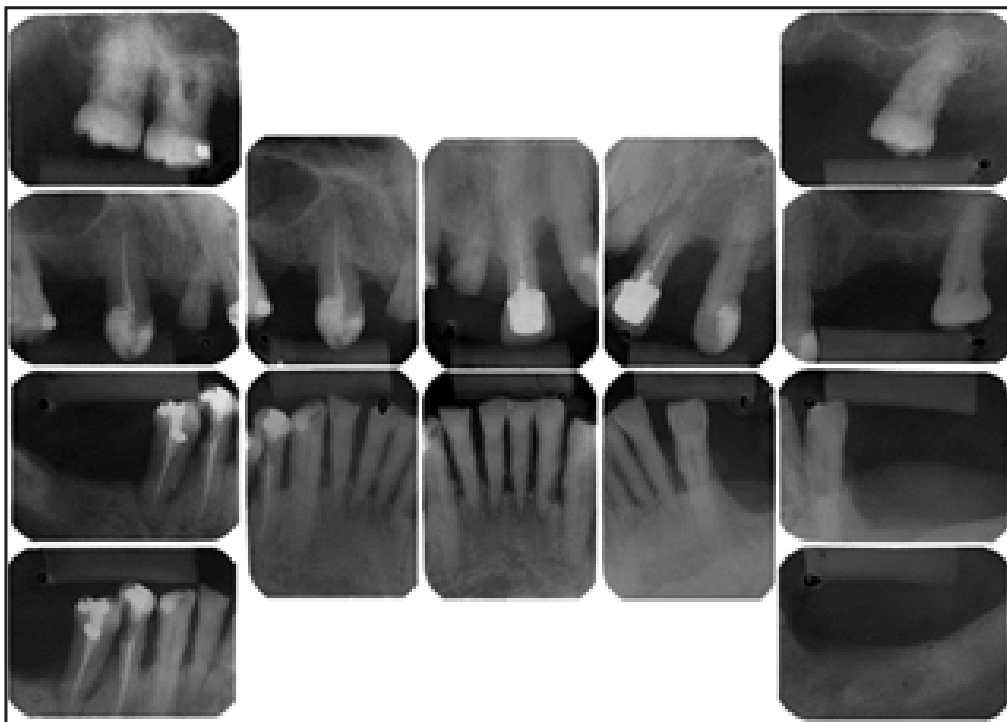
A 65-year-old male patient with no systemic problems looked for dental treatment complaining about his dental aesthetics and functional problems. His major desire was to improve his masticatory function by extraction of all remaining teeth and complete denture fabrication.

The intraoral examination revealed severe periodontitis in both the maxillary and mandibular arches associated with tooth extrusion, oblique fracture of the crown #11, unsatisfactory fixed prosthesis on tooth #21, missing teeth and occlusal collapse. Some impaired teeth presented probing depths varying between 3 to 9 mm. The most pronounced probing depths were concentrated in the mandibular anterior region (*Figure 1*). The clinical findings were supported by radiographic examination which showed severe bone loss around almost all teeth except the endodontically treated teeth #13, #21, #44 and #45 (*Figure 2*). After clinical and

Corresponding author: Fellippo Ramos Verri, Assistant Professor, Department of Dental Materials and Prosthodontics, UNESP – Univ Estadual Paulista, Aracatuba, São Paulo, Brazil. José Bonifácio St, 1193, Aracatuba, São Paulo 16015-050, Brazil, Tel: +55 1836363292; Fax: +55 – 1836363245; e-mail: fellippo@gmail.com



*Figure 1: Initial clinical case – Intraoral views (frontal).*



*Figure 2: Initial radiographic aspects.*

radiographic evaluation, diagnostic models were mounted on a semi adjustable articulator and the clinical procedures were planned including some tooth preservations which will be used for root-supported overdentures.

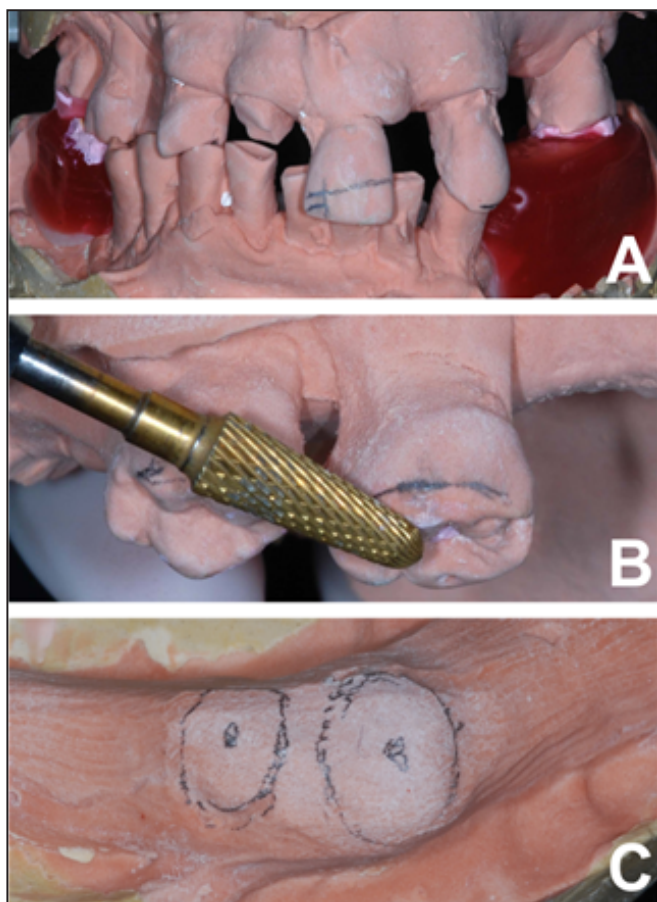
The initial treatment plan included extraction of teeth classified as impaired (#11, #16, #17, #27, #32, #31, #41, #42, #45); endodontic treatment of teeth #23, #33, #43; and endodontic retreatment of teeth #13, #21, and #44. These endodontically treated teeth were utilized to support and/or retain the permanent prosthesis. Maxillary and mandibular immediate dentures were planned to avoid patient problems caused by tooth loss between the initial surgery and the final overdenture insertion.

Alternative treatment planning included extraction of all teeth and fabrication of conventional complete dentures, implant-retained prosthesis or overdentures as mentioned above. All situations were discussed with the patient and he chose the overdenture fabrication treatment option.

### **Pre-surgical procedures**

Initially, endodontic procedures for teeth that would be used as support for the overdentures were completed. Then, impressions of maxillary and mandibular jaws were performed with irreversible hydrocolloid (Hydrogum, Zhermack, Rovigo, Italy) and the gypsum casts were obtained for immediate prosthesis fabrication. Next, conventional procedures for transfer and mounting of the casts in a semi-adjustable articulator were performed. For intermaxillary recording the maximum intercuspation position was used (*Figure 3*).

The surgery was planned on the gypsum models in the prosthetic laboratory. This surgery included removal of crowns that would receive the retention system in the future and all other teeth that would be extracted (*Figure 3*). It is necessary to highlight that reference lines (midline of the face and high smile line) were marked in the central incisor for locating the ideal planned position for the artificial teeth



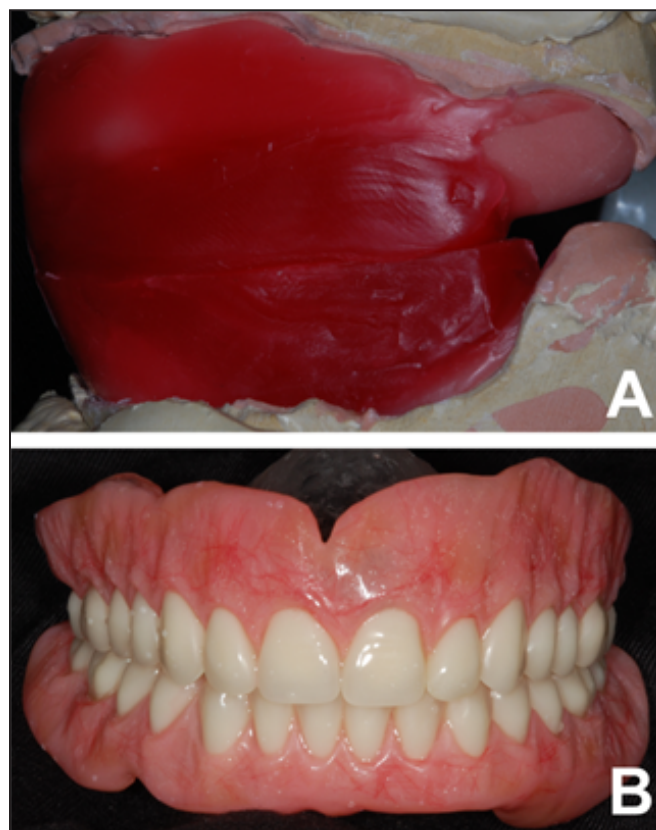**Figure 3:** (A) Models mounting on semi adjustable articulator and intermaxillary registration in maximum Intercusation; (B) Demonstration of gypsum model surgery; (C) Gypsum model surgery finalized.

arrangement. Since the patient didn't present with loss of occlusal vertical dimension, the denture was made with the wax occlusal rims keeping the initial vertical dimension presented by the patient. Attention was given to correct the curve of Spee in the initial wax plans by creating the curve of Spee on the maxillary cast.

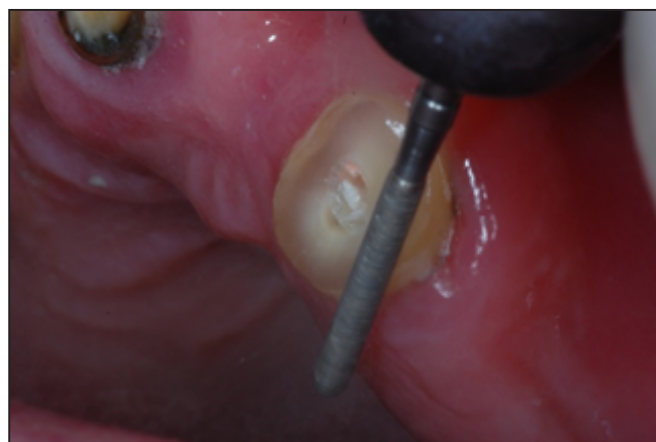Conventional procedures for artificial tooth arrangement and immediate denture processing were completed (Figure 4). Furthermore, before processing the models were duplicated to obtain a surgery guide in clear acrylic resin that would be used to check compression areas of the soft tissue during the surgery.

#### Trans-surgical procedures

After immediate denture processing the surgery was performed. Careful attention during the surgical procedure was given to the sectioning of the endodontically treated teeth. These teeth would serve as support/retention for the overdentures (Figure 5). These teeth were sectioned about 1mm above the gingival margin. Then, all other teeth were extracted according to the treatment plan and excess bone and/or gingival tissues were removed in the areas indicated by the clear acrylic surgical guide. Interrupted sutures were then placed with 6.0 nylon suture (Shalon, Sertix, Goiás, Brazil). Finally, minor adjustments were made to the internal surface, and borders and undercut areas of the immediate dentures were completed following the relines procedure using soft tissue conditioning material (Dentusoft, Densell, Buenos Aires, Argentina) (Figure 6) following installation (Figure 7).



**Figure 4:** (A) Occlusal rim and intermaxillary relations (B) Immediate dentures finalized.

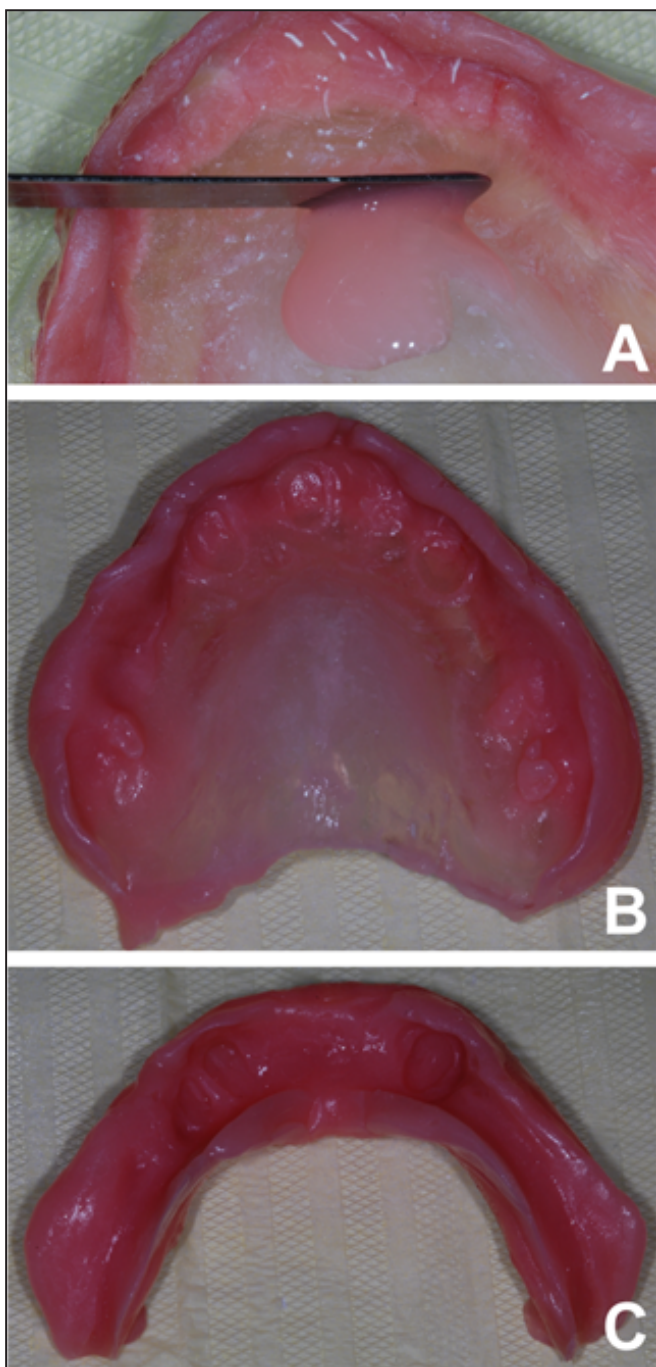


**Figure 5:** Sectioning procedure of the crown –Upper left canine.

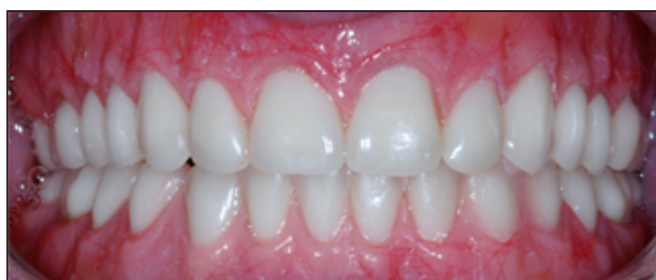The patient was medicated with amoxicillin 500 mg every 8 hours for 7 days, nimesulide 100 mg every 12 hours for 4 days and with paracetamol 750 mg for pain as necessary. After 7 days, the adaptation was reevaluated. It was determined that a relines at this appointment would not be necessary.

#### Overdenture procedures

During the temporary period all procedures focusing on definitive prostheses were planned. The support teeth received intraradicular preparation and the impressions were made by use of condensation silicone (Zetaplus/Oranwash L, Zhermack, Rovigo, Italy) by indirect technique using custom trays. Then, wax occlusal rims were registered in centric relation and mounted in a semi-adjustable articulator. After selection and arrangement of the artificial teeth were made (Trilux, Dental Vipi Ltda., Pirassununga, Brazil), a wax try-in was performed. The set-up and esthetics was accepted by

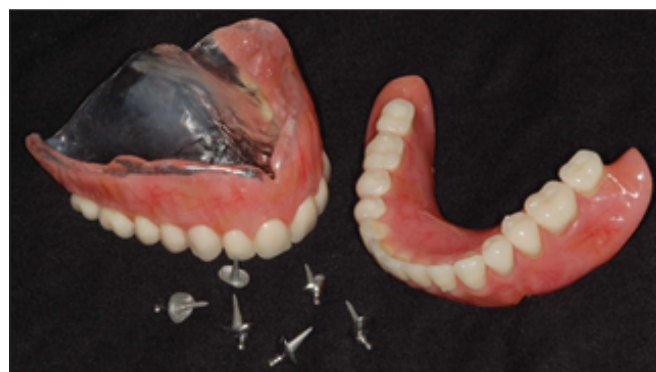

**Figure 6:** (A-C) Procedure of reline with tissue conditioning material (Dentusoft) in the immediate dentures.

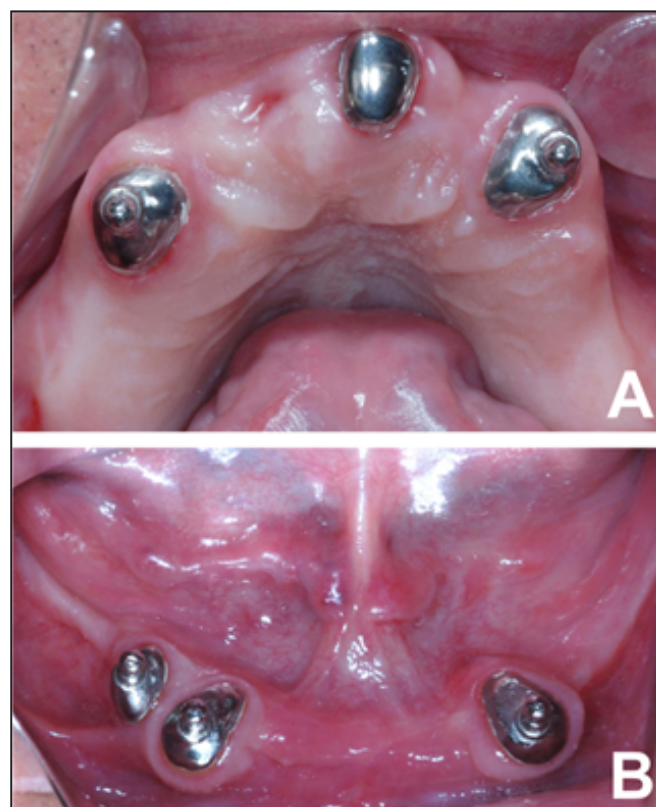


**Figure 7:** Installation of immediate dentures and occlusal adjustments.

the patient (Figure 8). Dentures processing was completed by conventional technique. The final dentures were adapted and adjusted before cementation of retention systems (Figure 9) which were cemented with zinc phosphate cement (SS White,



**Figure 8:** Overdentures finalized and retention system.

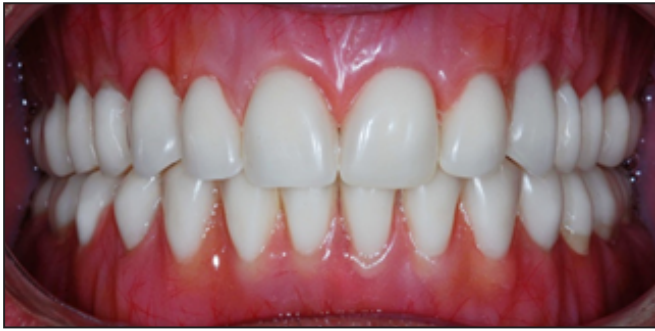

**Figure 9:** (A-B) Cementation of retention systems (O'ring).

Rio de Janeiro, RJ, Brasil). The system caps were captured by direct technique using self-curing resin (Pattern Resin LS, GC United Kingdom Ltd, Newport Pagnell, United Kingdom) (Figure 10). After insertion, periodic follow-up was planned. Initially, the patient returns to the dental clinic every week during the first month. Then he returned once a month for the next 5 months. The patient showed satisfaction with the final result of his treatment, and no complications were observed during this period.

### Discussion

The literature reports that in the elderly population it is common to observe poor dentition, affected by periodontal disease and dental caries. In certain situations, the patient is limited to being rehabilitated with complete dentures due to the fact that no other options are available. However, the use of select teeth in strategic positions can greatly improve the final treatment result in terms of overdenture stability and retention [7].



**Figure 10:** Installation of the overdentures after occlusal adjustment.

This improvement is accomplished by utilization of roots to support, stabilize and retain the overdenture. These alternatives offer the patient a more comfortable prosthesis, especially in the mandibular arch rehabilitation where achievement of functional requirements of the complete dentures with respect to retention, support and stability are limited [8].

Among possible roots to be used to support the overdenture the canine is a tooth that better exhibits characteristics associated with support. This occurs because of its large root with greater periodontal area for attachment and also due to its localization in the transition area between anterior and posterior teeth [13]. By utilizing four canines it is shown that satisfactory retention was accomplished. Thus, this fact could have contributed to the patient's satisfaction in relation to retention and stability of the final prosthesis.

Another advantage of this clinical case was the maintenance of the occlusal vertical dimension with relative accuracy by immediate denture utilization. Natural teeth utilization facilitates determination of centric relation [6]. It is important to emphasize that after dental extractions, it is necessary to have periodic relines done on the prostheses

due to bone reabsorption to avoid movement. Moreover, the principal advantage of the immediate dentures was the fact that the patient has not been impaired in his social integration after surgery, because socializing and daily routines can be continued with no great problems [5].

The choice of ball attachment (O'ring) in this clinical report was considered because this attachment exhibits a simple design, easy maintenance and allows multi-directional movement of the retentive housing. This system provides vertical movement during mastication allowing minimum stress transferred to supporting roots, directing the occlusal force to supporting soft tissues. However, it is necessary to inform the patient that the elastic inserts (o'rings) of this system are affected by wear, resulting in a gradually loss of retention. Consequently, there is need for follow-up appointments to check the hygiene situation and the eventual replacement of the elastic insert(s) when retention levels begin to decrease [13,14].

Finally, one of the most important requirements to the success of overdentures is the patient's awareness of their need to improve oral hygiene of the remaining roots used for support and/or retention. The patient must be instructed to correct techniques of oral hygiene to improve considerably the longevity of the oral rehabilitation as long as possible [8].

## Conclusion

The use of immediate denture fabrication for temporary rehabilitation prior to definitive overdentures can provide comfort to the patient during the treatment. The root supported overdenture is a better alternative for a treatment option to conventional dentures since the proprioception is maintained and improves stability and retention. It is necessary to have patient awareness about good oral hygiene to maintain the roots so that treatment remains satisfactory for a long time.

## References

1. Okoje VN, Dosumu OO, Alonge TO, Onyeaso C. Tooth loss: are the patients prepared? *Nigerian Journal of Clinical Practice*. 2012; **15**: 172-175.
2. De Marchi RJ, Hilgert JB, Hugo FN, Santos CM, Martins AB et al. Four-year incidence and predictors of tooth loss among older adults in a southern Brazilian city. *Community Dentistry and Oral Epidemiology*. 2012; **40**: 396-405.
3. Saintrain MV, de Souza EH. Impact of tooth loss on the quality of life. *Gerodontology*. 2012; **29**: e632-636.
4. De Marchi RJ, Leal AF, Padilha DM, Brondani MA. Vulnerability and the psychosocial aspects of tooth loss in old age: a Southern Brazilian study. *Journal of Cross-Cultural Gerontology*. 2012; **27**: 239-258.
5. Gilboa I, Cardash HS. An alternative approach to the immediate overdenture. *The International Journal of Prosthodontics*. 2009; **18**: 71-75.
6. Shah FK, Gebreel A, Elshokouki AH, Habib AA, Porwal A. Comparison of immediate complete denture, tooth and implant-supported overdenture on vertical dimension and muscle activity. *International Journal of Prosthodontics*. 2012; **4**: 61-71.
7. Hug S, Mantokoudis D, Mericske-Stern R. Clinical evaluation of 3 overdenture concepts with tooth roots and implants: 2-year results. *International Journal of Prosthodontics*. 2006; **19**: 236-243.
8. Brkovic-Popovic S, Stanisic-Sinobad D, Postic SD, Djukanovic D. Radiographic changes in alveolar bone height on overdenture abutments: a longitudinal study. *Gerodontology*. 2008; **25**: 118-223.
9. Dileep Nag V, Ravindra P, Thirupathi Reddy BA. Simplified chair-side technique with pre-fabricated directional rings in a case of divergent root retained overdenture. *Journal of Indian Prosthodontic Society*. 2011; **11**: 130-132.
10. ShindeGorakhnath B, Wadkar, AP. Overdenture: a way of preventive prosthodontics. *Indian Journal of Dental Research*. 2012; **4**: 863-865.
11. Schuch C, de Moraes AP, Sarkis-Onofre R, Pereira-Cenci T, Boscato N. An alternative method for the fabrication of a root-supported overdenture: A clinical report. *Journal of Prosthetic Dentistry*. 2013; **109**: 1-4.
12. Gonda T, Ikebe K, Ono T, Nokubi T. Effect of magnetic attachment with stress breaker on lateral stress to abutment tooth under overdenture. *Journal of Oral Rehabilitation*. 2004; **31**:1001-1006.
13. Jayasree K, Bharathi M, Nag V, Vinod B. Precision Attachment: Retained Over denture. *Journal of Indian Prosthodontic Society*. 2012; **12**: 59-62.
14. Cheng T, Sun G, Huo J, He X, Wang Y, et al. Patient satisfaction and masticatory efficiency of single implant-retained mandibular overdentures using the stud and magnetic attachments. *Journal of Dentistry*. 2012; **40**: 1018-1023.