

# Duration of the Peak of Growth in Class I And III Subjects using the Baccetti's Cervical Vertebrae Maturation Analysis on Lateral Cephalometric Radiographs

Augusto Gabriel García-Drago<sup>1</sup>, Luis Ernesto Arriola-Guillén<sup>2,3</sup>

<sup>1</sup>Associate Professor and Specialist Oral and Maxillofacial Radiology, USMP and Masters in Bucal and Maxillofacial Radiology, Universidad Peruana de Ciencias Aplicadas - UPC, Perú. <sup>2</sup>Associate Professor, Division of Orthodontics, Faculty of Dentistry, Universidad Científica del Sur - UCSUR, Lima, Perú. <sup>3</sup>Universidad Nacional Mayor de San Marcos - UNMSM, Lima, Perú.

## Abstract

**Objective:** To compare the duration of the pubertal growth peak in Class I and Class III patients according to Baccetti's cervical vertebral analysis on lateral cephalometric radiographs.

**Materials and Methods:** The design of this study was descriptive, cross-sectional, and comparative. The sample consisted of 115 radiographs from patients aged 9-15 years old. The evaluation of skeletal maturation stage was performed using a visual analysis of C3 and C4 cervical vertebrae. Also, the skeletal relation was evaluated according to Steiner analysis. Evaluations were performed independently by two examiners previously trained and calibrated. We used the Kappa coefficient to calculate the intra and inter-observer. The pubertal peak duration was calculated from the age in which stages CS3 and CS4 appeared in the cervical vertebrae.

**Results:** The average duration of the pubertal growth peak in Class I patients was  $9.72 \pm 1.44$  months and  $14.52 \pm 0.95$  months in Class III patients. A difference of 4.8 months ( $p < 0.001$ ) was found.

**Conclusions:** The duration of pubertal growth spurt was 4.8 months higher in patients with Class III skeletal relation. This condition can increase the development of the mandible for Class III patients.

*Key Words:* Skeletal maturation, Cervical stage, Pubertal growth spurt, Skeletal relationship, Baccetti's method (CVM).

## Introduction

Sequential growth and remodelling of the mandible in children is of great interest because of their important role in the orthodontic treatment [1]. The identification of growth acceleration periods can significantly contribute to correct osseous imbalances and is linked to dentofacial orthopaedics optimal timing [2]. An understanding of the normal processes of growth will allow distinguishing orthodontic and orthopaedic treatment effects of the changes that occur during normal pubertal growth [3]. In this regard, biological indicators of skeletal maturity relate primarily to somatic pubertal changes [4]. Individual variations on onset, duration and termination of pubertal outbreak have been identified in the mandibular growth [5].

Cephalometric cervical vertebrae studies related to mandibular growth allow researchers to acquire craneofacial growth information [1-2,5]. Cervical Vertebral Maturation (CVM) method has great validity in the skeletal maturation assessment during the pubertal growth and detecting the pubertal growth peak (interval between skeletal stage 3 (CS3) and skeletal stage 4 (CS4) [1-2,6] Baccetti's vertebral analysis in lateral cephalograms has the same validity as the hand-wrist bone analysis. The advantage is that a second radiographic exposition will not be needed reducing the radiation exposure on subjects under growth [6-7].

Multiple orthodontic treatment modalities, orthopaedics and surgery have evolved to correct Class III skeletal

patients. However, this type of discrepancy is still difficult for orthodontists due to various etiologies. Development of Class III disharmony is multifactorial and complex and may result from combinations of skeletal and dental characteristics with variations in magnitude, direction and timing of facial growth [8].

Excessive mandibular growth appears to play an important role in determining long-term adverse outcomes of Class III orthopaedic treatments [7]. Information on the development and growth in patients with malocclusion and dentoskeletal disharmonies is very important to diagnose and plan an appropriate orthodontic treatment [9]. Deguchi et al. [10] reported that growth trends in Class III malocclusion might differ from those of subjects with normal facial and occlusal developmental patterns, because peak growth occurs rather late. Additional information about the growth characteristics of Class III patients has been reported [11]. The author emphasized that the largest increments for mandibular length in the male subjects were at the oldest age interval (15 years and older), indicating the growth spurt at this late age period. The CVM method has gained popularity because of its validity in assessing skeletal maturation during the circumpubertal period and in detecting the growth spurt (interval between Cervical Stage 3 (CS3) and Cervical Stage 4 (CS4) [12].

One previous investigation, reported larger increases in mandibular length during the pubertal spurt for Class III subjects related to a higher duration of the pubertal peak when compared to subjects with normal skeletal relationship [13].

However, more studies related to this topic are needed to support this hypothesis.

The aim of this study was to compare the pubertal growth spurt duration in Class I and Class III subjects as assessed with the Baccetti's cervical vertebral analysis in lateral cephalograms. This information would be valuable for diagnosis and treatment planning for this type of malocclusion.

### Materials and Methods

The design was descriptive and cross-sectional study, and was approved by a local ethics committee. The material of this study included lateral cephalometric radiographs of 115 patients, aged 9-15 years, selected from a series of records, from the archives from a private dental imaging centre (CDI Diagnostic Center, Lima, Perú). Sample size was calculated considering the comparison for two means formula (comparison of the mean of the pubertal growth spurt duration in patients with skeletal Class I and Class III) with a confidence of 95% and power 80%. The sample required was 20 subjects per group, but included more subjects per group. The sample consisted of four groups (65 Class I subjects), 41 with skeletal maturity of CS3 and 24 with skeletal maturity of CS4 and 50 Class III subjects: 21 with skeletal maturity of CS3 and 29 with CS4 skeletal maturity (Table 1).

To be included in the study, patients had to satisfy all of the following inclusion criteria:

- Cephalograms of good quality.
- Skeletal Class I or III.
- Skeletal stages CS3 or CS4 based on the CVM.
- Complete visualization of the second (C2), third (C3), and fourth (C4) cervical vertebrae.

In addition to these inclusion criteria, patients with systemic or osseous disease that impact in the developmental growth, with known craniofacial syndromes, under active orthodontic treatment or with prior history of orthognatic or cervical vertebrae surgery, or permanent tooth loss were not considered in this investigation.

Lateral radiographs were taken by one radiology technician with experience. Imaging was performed with digital cephalometric panoramic equipment (ProMax®, Planmeca, Finland). Device settings were set at 16mA, 72 kV and 9.9 seconds. Cephalometric analyses were analysed by means of a Lg flatron L1900r-Bf monitor of 19 inches and with Planmeca Romexis® software. The lateral cephalograms of the Class III subjects were staged according to the CVM method [4] (Figure 1) It comprises 6 stages (CS) from CS1

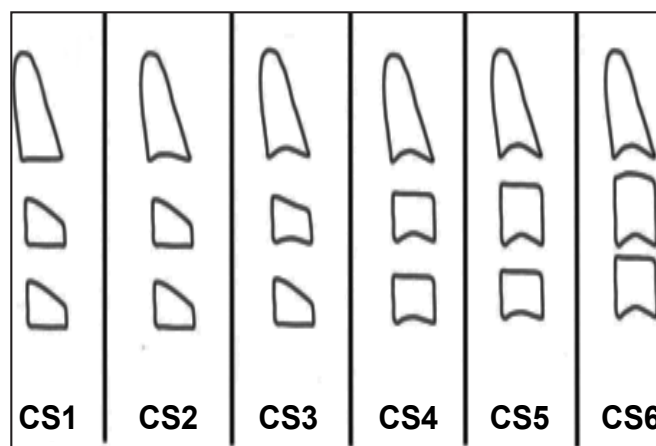


Figure 1. Lateral cephalograms of the Class III subjects according to the CVM method.

through CS6. In subjects with normal occlusion, the growth spurt occurs between CS3 and CS4. The morphology of the three cervical vertebrae (C2,C3,C4) was evaluated by visual inspection and then classified in a CS3 or CS4 stage. Presence or absence of a concavity at the lower border of the body of C2, C3, and C4 and shape of the body of C3 and C4 were also considered. The onset of the pubertal growth spurt for the CS3 stage was identified by the presence of a concavity on the lower border of C2 and C3 and rectangular C3 and C4 bodies. The end of the pubertal growth spurt was identified on CS4 stage by the presence of a concavity of the lower border of C4 and both C3 and C4 bodies with almost squared shape. The skeletal relation evaluation was performed according to the Steiner analysis. ANB angle was determined and analysed for each patient. Patients were classified into 2 groups according to skeletal pattern: skeletal Class I (ANB= 2° ± 2°) and Class III (ANB<0°).

Cephalometric tracings were performed by two orthodontist previously calibrated, with experience drawing cephalograms. Any disagreement between observers was resolved by discussion. The intra and inter observer agreement was assessed with the kappa coefficient, which gave a result of 0.90 for skeletal stage maturity and 0.92 for skeletal relation.

### Statistical analysis

All statistical analyses were performed using SPSS ver.21 for Windows (IBM SPSS, Armonk, NY, USA). Descriptive statistics were obtained for age in years for skeletal Class I or III and by skeletal maturity (CS3 and CS4). The Shapiro-Wilks test revealed lack of normality of distribution for the data. Consequently, the Mann-Whitney U test for independent samples was used to identify significant differences (p<0.05)

### Results

ANB angle distribution and the mandibular plane inclination (FGoMe) according to cervical vertebrae stage and the skeletal relation are shown in Table 2. The skeletal relation was confirmed in these patients. A negative ANB was observed in Class III subjects with a mean of -0.73 in CS3 and -1.51 in CS4. Table 3 shows the average age of onset and end of growth according to the skeletal relation. No statistical significant differences were found for CS3 (p=0.92) or for CS4 (p=0.23). However the duration mean of the pubertal growth spurt was of 9.72 ± 1.44 months in Class I patients

Table 1. Sample distribution according to sex, skeletal relation and cervical vertebral stage.

Skeletal relation	Cervical vertebral stage	Sex		TOTAL
		Female	Male	
Class I	CS3	21	20	41
	CS4	20	4	24
		41	24	65
Class III	CS3	8	13	21
	CS4	20	9	29
		28	22	50
<b>TOTAL</b>		<b>69</b>	<b>46</b>	<b>115</b>

and of  $14.52 \pm 0.95$  in Class III patients (Table 4). Statistical significance differences of 4.8 months were found between both patients ( $p < 0.001$ ).

### Discussion

The pubertal growth spurt is a developmental growth stage in which maximum growth will occur in a short period of time. However, literature suggests that the duration of pubertal growth spurt may vary in patients with different skeletal relation. In our study, the sample was collected retrospectively. A previous pilot study was performed considering 10 subjects. Results showed that the pubertal growth spurt duration was higher on Class III patients compared to Class I patients. Also, reliability and viability of the methodology was determined. The sample was collected and recorded by a technician with experience in radiology and two independent dentists' previously calibrated performed the observations. Kappa coefficient was very good for all observers.

CVM method has been proposed as an effective diagnostic tool to assess the adolescent peak growth spurt both in body height and mandibular size [2,15]. This method has been also suggested as extremely useful for orthodontic decision making or for the long-term evaluation of treatment outcomes [2].

The present study verified that the duration of the pubertal growth peak was higher in Class III patients. The 4.8 months of difference was significant when compared to Class I patients. Class III pubertal growth spurt duration was one third higher than for Class I patients. Moreover, genetic factors, life styles, environment, ethnic origins and sex, can be consider to be related to these results.

According to Kuc-Michalska et al. [13] the duration of the pubertal growth spurt was of 11 months for Class I and 16 months for Class III respectively with a difference of 5 months. This study showed similar findings; A difference of 4.8 months was seen between both skeletal patients. Also, the duration of the pubertal growth spurt in Class I and III individuals was shorter than the one reported by Kuc-Michalska et al. [13] (Class I: 9.72 months and Class III: 14.52). This can be attributed to the type of population, as the Caucasian population can be considered bigger when compared to the Latin American population.

Baccetti et al. [14] reported that the mean duration of the pubertal growth spurt was of 18 months in Class III boys and girls. The investigated sample consisted of 1091 pre-treatment lateral cephalometric records; these results confirm the hypothesis of this paper.

Finally, the duration of pubertal growth spurt was 5 months higher in patients with class III skeletal relation. This condition can increase de development of the mandible for class III patients. Longitudinal studies of the pubertal growth spurt duration in Class III patients are also recommended.

### Conclusions

The duration of pubertal growth spurt was 4.8 months higher in patients with Class III skeletal relation. This condition can increase de development of the mandible for Class III patients.

### Acknowledgement

The authors are thankful to Dr. Hugo Aguayo from the CDI Diagnostic Center for providing all the facilities during the investigation.

**Table 2.** Characteristics of the sample by of cervical vertebral stages and skeletal relation.

Skeletal relation	Cervical vertebral stage	Mean	SD
Class I	CS3	ANB	2.70
		FGoMe	27.46
	CS4	ANB	2.65
		FGoMe	25.92
Class III	CS3	ANB	-0.73
		FGoMe	25.84
	CS4	ANB	-1.51
		FGoMe	26.76

**Table 3.** Age of onset of cervical vertebral stages by skeletal relation.

Skeletal relation	Cervical vertebral stage	AGE							p
		n	Mean	SD	S <sup>2</sup>	Max	Min	Range	
Class I	CS3	41	11.74	1.34	1.81	13.50	9.00	4.50	0.92
Class III	CS3	21	11.71	1.27	1.61	13.58	10.00	3.58	
Class I	CS4	24	12.55	1.55	2.42	14.92	9.83	5.09	0.23
Class III	CS4	29	12.92	0.63	0.40	14.00	11.00	3.00	

\* Mann-Whitney U test for independent samples

**Table 4.** Mean interval duration of the peak puberal interval on Class I and III subjects.

Skeletal relation	Cervical vertebral stage		
	CS4	CS3	CS4-CS3
Class I	12.55	11.74	0.81 years = 9.72 months ± 1.44
Class III	12.92	11.71	1.21 years = 14.52 month ± 0.95

$p < 0.001$

\* Mann-Whitney U test for independent samples

## References

1. Gu Y, McNamara JA. Mandibular growth changes and cervical vertebral maturation. A cephalometric implant study. *Angle Orthod.* 2007; 77: 947-953.
2. Baccetti T, Franchi L, McNamara JA Jr. An improved version of the Cervical Vertebral Maturation (CVM) method for the assessment of mandibular growth. *Angle Orthodontics.* 2002; 72: 316-323.
3. Lewis AB, Roche AF, Wagner B. Growth of the mandible during pubescence. *Angle Orthodontist.* 1982; 52: 325-342.
4. Baccetti T, Franchi L, McNamara J Jr. The Cervical Vertebral Maturation (CVM) method for the assessment of optimal treatment timing in dentofacial orthopedics. *Seminars in Orthodontics.* 2005; 11: 119-129.
5. Franchi L, Baccetti T, McNamara JA Jr. Thin-plate spline analysis of mandibular growth. *Angle Orthodontist.* 2001; 71: 83-89.
6. Gandini P, Mancini M, Andreani F. A comparison of hand-wrist bone and cervical vertebral analyses in measuring skeletal maturation. *Angle Orthodontist.* 2006; 76 : 984-989.
7. Westwood PV, McNamara JA Jr, Baccetti T, Franchi L, Sarver DM. Long-term effects of Class III treatment with rapid maxillary expansion and facemask therapy followed by fixed appliances. *American Journal of Orthodontics & Dentofacial Orthopedics.* 2003; 123: 306-320.
8. Alexander AE, McNamara JA Jr, Franchi L, Baccetti T. Semilongitudinal cephalometric study of craniofacial growth in untreated Class III malocclusion. *American Journal of Orthodontics and Dentofacial Orthopedics.* 2009; 135: 700-714; discussion 700-701.
9. Reyes BC, Baccetti T, McNamara JA Jr. An estimate of craniofacial growth in Class III malocclusion. *Angle Orthodontist.* 2006; 76: 577-584.
10. Deguchi T, Kuroda T, Minoshima Y, Graber TM. Craniofacial features of patients with Class III abnormalities: Growth-related changes and effects of short-term and long-term chin cup therapy. *American Journal of Orthodontics and Dentofacial Orthopedics.* 2002; 121: 84-92.
11. Battagel JM. The aetiological factors in Class III malocclusion. *European Journal of Orthodontics.* 1993; 15: 347-370.
12. Franchi L, Baccetti T, McNamara JA Jr. Mandibular growth as related to cervical vertebral maturation and body height. *American Journal of Orthodontics and Dentofacial Orthopedics.* 2000; 118: 335-340.
13. Kuc-Michalska M, Baccetti T. Duration of the pubertal peak in skeletal Class I and Class III subjects. *Angle Orthodontist.* 2010; 80: 54-57.
14. Baccetti T, Reyes BC, McNamara JA Jr. Craniofacial changes in Class III malocclusion as related to skeletal and dental maturation. *American Journal of Orthodontics and Dentofacial Orthopedics.* 2007; 132: 112-171.
15. San Roman P, Palma JC, Oteo MD, Nevado E. Skeletal maturation determined by cervical vertebrae development. *European Journal of Orthodontics.* 2002; 24: 303-311.