

Attention Deficit Hyperactivity Disorder and Co-Morbidity in Old Age

Weusten LH¹, Sobczak S¹, Rosowsky E², Heijnen-Kohl SMJ¹, Hoff EI³ and van Alphen SPJ^{1,4}

¹Department of Old Age Psychiatry, Mondriaan Hospital, Heerlen-Maastricht, The Netherlands

²Harvard Medical School, Boston, Massachusetts, USA

³Department of Neurology, Zuyderland Medical Center, Heerlen, The Netherlands

⁴Department of Clinical and Life Span Psychology, Free University of Brussels (VUB), Brussels, Belgium

Corresponding author: Weusten LH, Department of Old Age Psychiatry, Mondriaan Hospital, Kloosterkensweg 10, 6419 PJ Heerlen, The Netherlands, Tel: +3188-5066363; Fax: +3188-5066680; E-mail: L.weusten@mondriaan.eu

Rec date: Jun 07, 2016; **Acc date:** Jun 30, 2016; **Pub date:** Jul 03, 2016

Copyright: © 2015 Weusten LH, et al. This is an open-access article distributed under the terms of the Creative Commons Attribution License, which permits unrestricted use, distribution, and reproduction in any medium, provided the original author and source are credited.

Abstract

Attention deficit hyperactivity disorder (ADHD) may persist into old age with prevalence rates up to 4.4%. We present a case report of an 80-year old man with ADHD complicated by personality pathology and a mild impairment in some executive functions. We illustrate that ADHD in older adults may be misdiagnosed for a neurodegenerative disease or personality disorder. To differentiate ADHD from neurodegenerative diseases or personality disorders, it is important to focus on the course of the problems by obtaining a complete history and a long term follow-up.

Keywords: ADHD; Personality disorder; Neurodegenerative disease; Frontotemporal dementia

Introduction

Attention deficit hyperactivity disorder (ADHD) is characterized by symptoms of inattention and/or hyperactivity and impulsivity. Little is known about ADHD in older adults. A few studies indicate that ADHD also persists into old age with prevalence ranging between 2.5 and 4.4% [1,2]. The treatment of ADHD in adults includes psychotherapy and pharmacotherapy with stimulants, mostly methylphenidate. A pilot study by [3] suggests that older adults have a similar response to methylphenidate as do younger adults.

In older adults with cognitive or behavioral problems neurodegenerative diseases are usually the first consideration. It is however important to differentiate neurodegenerative disorders from ADHD [1,4]. Personality disorders (PDs) should also be considered in the differential diagnosis. The following case illustrates the complexity of the diagnostic assessment of ADHD in later life.

Case

A.B., an 80-year old former veterinarian, was referred to our department of old age psychiatry. According to his wife his impulsive and egocentric behavior had increased substantially since his retirement 15 years ago. He purchased things excessively and went flamingo dancing almost every day. In general, he was experienced as being offensive, and chronic relationship issues developed. In the past two years his wife also noticed memory deficits, and believed her husband was suffering from dementia.

The patient denied any deterioration, but claimed that his environment had become less tolerant with his eccentric behavior. He was quite cheerful and longwinded, but did not display psychotic symptoms. A.B. reported no history of psychiatric treatment, however he did report a history of periods of excessive alcohol consumption. His medical history included diabetes mellitus type II, chronic

obstructive pulmonary disease and arthritis and “cured” prostate cancer. His medications included calcium, vitamin D, sodium bicarbonate 500 mg 3dd1, colchicine 0.5 mg 1-2dd1, simvastatin 20 mg 1dd1, salmeterol oral inhaler and glimepiride 3 mg 1dd1. The history is notable for the patient’s mother having been diagnosed with dementia in “old age”.

At this stage we suspected a neurodegenerative disease such as frontotemporal dementia (FTD) based on the described heightened personality characteristics along with a lack of empathy. The possibility of a premorbid PD and ADHD were also considered, because of life-long impulsive and chaotic behavior. The patient’s current presentation was ruled out as a hypomanic episode given his life-long history of mild euphoria and impulsivity.

Neurological and Neuropsychological Assessment

On neurological examination there was no functional loss and Parkinsonism was discerned. Tendon reflexes were low to absent. Plantar reflexes were normal. Brain MRI showed some generalized cortical atrophy (most likely age-related) and a few punctate cerebral white matter hyperintensities (most likely microvascular in origin, secondary to the diabetes). Cerebral spinal fluid (CSF) analysis revealed a slightly elevated tau protein (383 ng/L; ref <350); beta amyloid and phosphorylated tau were within normal range. The slightly elevated tau protein can be found in neurodegenerative disorders such as FTD, however it is not specific. It can also be found in psychiatric disorders and in normal aging, as these can result in dysfunction of the frontal cortico-subcortical circuits [5].

The neuropsychological examination was clearly structured as the patient tended to be chatty and inconsistently focused. The mental flexibility on the Trail Making Test (Trail B) was impaired and the Clock Drawing Test was executed suboptimally. The other tasks assessing executive functions showed no deficits. These included the Stroop Color- Word Test, Digit Span, Fluency, Key Search (a subtest of the Behavioral Assessment of Dysexecutive Syndrome) and Meander (a visuomotor alternating test). No impairments were identified

through the other cognitive tests (MMSE, 15 Word Learning Task, Visual Association Test, direct and delayed reproduction of a story, Letter Digit Symbol Test, Clock reading).

ADHD and Personality Assessment

In a diagnostic interview to assess ADHD in adults, the DIVA 2.0 [6], the criteria were met for ADHD with a combined presentation in adulthood and a hyperactive-impulsive presentation in childhood. The DIVA 2.0 was also conducted as an informant interview with the patient's wife, covering the period of adulthood before his retirement. The criteria were met for an inattentive presentation of ADHD accompanied by some hyperactive-impulsive symptoms. It was concluded that ADHD was important in the clinical presentation of this patient.

A.B. and his wife both described him as someone who had always been self-focused, impulsive, a fearless risk-taker, and as someone who loved being the center of attention. Initially, his wife described an exacerbation of these traits following his retirement. However, when this was addressed more extensively, she reported increasing behavioral problems for the past 30-35 years, especially her husbands' lack of responsibility and empathy.

The HAP [7], an informant questionnaire to assess maladaptive personality traits, was completed by his wife and a son with a reliable response tendency (Figure 1). According to both informants the patient was minimally vulnerable in social interactions, highly self-confident and self-righteous, consistent with narcissistic traits and tendencies. They furthermore reported that the patient was very chaotic, impulsive and capricious, which could also be consistent with a diagnostic picture of ADHD.

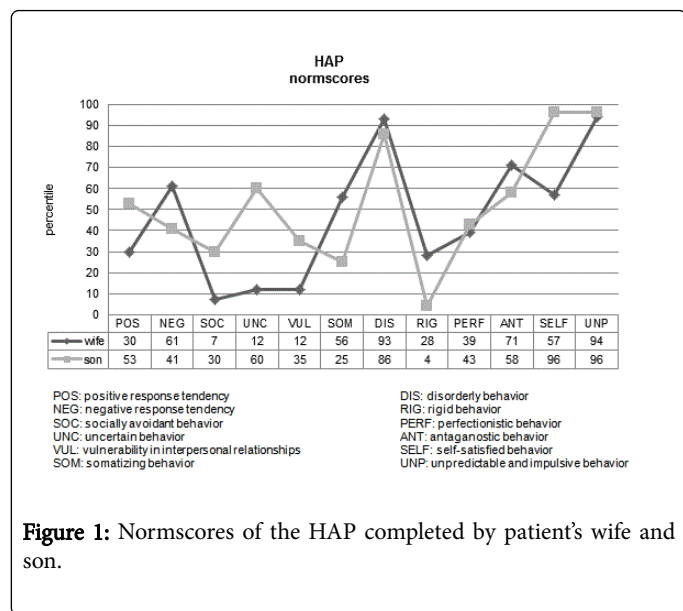


Figure 1: Normscores of the HAP completed by patient's wife and son.

Follow-up

Two years later the patient returned for re-evaluation of his cognitive functioning. He had not been managing his diabetes well for years. He reported being fatigued and spending considerable time secluded in his room. He did not report depressive symptoms. Neuropsychological examination and brain MRI showed no changes when compared to the studies two years earlier.

Conclusion

A.B.'s biographical information indicated a history of marked egocentrism and a limited ability to feel fear. In our opinion, the maladaptive personality traits cannot sufficiently be accounted for by ADHD. We diagnosed ADHD and a co-morbid PD with narcissistic and histrionic traits. This was complicated by a non-progressive mild cognitive impairment impacting some executive functions (mental flexibility and clock drawing). A neurodegenerative disease was deemed unlikely, based on the almost lifelong behavioral symptomatology and the CSF analysis alone providing insufficient evidence for a tauopathy.

Discussion

Studies demonstrate that ADHD in adults is associated with impairments in attention, behavioral inhibition and memory [8]. Many neuro-imaging studies support a relationship between ADHD and compromised white matter integrity of the frontal-striatal, fronto-temporal and fronto-parietal regions [4,9]. In older adults one could therefore incorrectly diagnose mild cognitive impairments (MCIs), behavioral symptomatology and imaging abnormalities associated with ADHD as being due to neurodegenerative disease [1,4].

Firstly, our case of A.B. illustrates the differential diagnosis between ADHD in older adults and neurodegenerative disorders. Beside a thorough assessment of the course of the problems, it is highly important to obtain a complete history of the patient's behaviors and clinical presentations. One might consider including an ADHD screening tool in the routine evaluation of MCI presenting as predominately attentional deficits [4]. The ADHD screening tool for adults by Barkley and Murphy may be useful for older adults [10].

Secondly, our case shows the diagnostic complexity of ADHD in older adults and co-morbid PDs. The PDs with impulsive traits show substantial overlap in symptomology with ADHD. Due to this overlap, one could misdiagnose ADHD for a PD. The emphasis of personality assessment in older adults lies commonly on autobiographic and informant information [11]. Therefore, the HAP is a valuable informant instrument as it is validated for older adults [7].

Thirdly, one should be mindful that relationship issues might distort the perception of and reporting by the informant. In our case the patient's wife experienced more relational stress as she was confronted more after his retirement with his longstanding behavior.

References

- Ivanchak N, Fletcher K, Jicha GA (2012) Attention-Deficit/Hyperactivity Disorder in older adults: prevalence and possible connections to Mild Cognitive Impairment. *Curr Psychiatry Rep* 14: 552-560.
- Michielsen M, Semeijn E, Comijs HC, van de Ven P, Beekman AT, et al. (2012) Prevalence of attention-deficit hyperactivity disorder in older adults in The Netherlands. *Br J Psychiatry* 201: 298-305.
- Manor I, Rozen S, Zemishlani Z, Weizman A, Zalsman G (2012) When does it end? Attention-deficit/hyperactivity disorder in the middle aged and older populations. *Clin Neuropharmacol* 34: 148-154.
- Ivanchak N, Abner EL, Carr SA, Freeman SJ, Seybert A, et al. (2011) Attention-Deficit/Hyperactivity Disorder in childhood is associated with cognitive test profiles in the geriatric population but not with Mild Cognitive Impairment or Alzheimer's Disease. *Journal of Aging Research*: 729801.
- Krudop W, Kerssens C, Dols A, Prins N, van der Flier W, et al. (2013) Frontotemporale demencie en de psychiatrische differentiaaldiagnose:

- twee gevalsbeschrijvingen en de rationale van de 'Laat Ontstaan Frontaal syndroom (LOF)-studie'. *Tijdschrift voor Neuropsychiatrie en Gedragsneurologie*: 72-79.
6. http://www.divacenter.eu/Content/VertalingPDFs/DIVA_2_EN_FORM%20-%20invulbaar.pdf
 7. <http://www.nkop.nl/praktijk/meetinstrumenten/instrument/?instrument=22>
 8. Seidman LJ, Doyle A, Freid R, Valera E, Crum K, et al. (2004) Neuropsychological function in adults with attention-deficit/hyperactivity disorder. *Psychiatr Clin North Am* 27: 261-282.
 9. Weyandt L, Swentosky A, Gudmundsdottir BG (2013) Neuroimaging and ADHD: fMRI, PET, DTI Findings, and Methodological Limitations. *Developmental Neuropsychology* 38: 211-225.
 10. Semeijn EJ, Michielsens M, Comijs HC, Deeg DJ, Beekman AT, et al. (2013) Criterion Validity of an Attention Deficit Hyperactivity Disorder (ADHD): Screening List for Screening ADHD in Older Adults Aged 60-94 years. *Am J Geriatr Psychiatry* 21: 631-635.
 11. van Alphen SPJ, Sadavoy J, Derksen JJJ, Rosowsky E (2012) Features and challenges of personality disorders in late life. *Aging Ment Health* 16: 805-810.

This article was originally published in a special issue, entitled: "**Elderly Health Care**", Edited by Wadie I. Najm