

A Very Low Birth Weight Infant with Severe Red Blood Cell Polyagglutination: A Case Report

Naoshi Yamada^{1*}, Yuki Kodama¹, Tomoko Goto¹, Rie Yamashita¹, Kotaro Doi¹, Masatoki Kaneko¹, Yuichiro Sato², Hiroshi Sameshima¹

¹Department of Obstetrics and Gynecology, Center for Perinatal Medicine, University of Miyazaki Hospital, Miyazaki City, Japan;

²Department of Diagnostic Pathology, Division of Pathology, University of Miyazaki Hospital Miyazaki City, Japan

INTRODUCTION

Polyagglutination is a rare condition in which cryptic erythrocyte membrane antigens (T, Th, Tk, Tn) on the surface of erythrocytes react with anti-T antibodies present in adult serum [1]. Although it does not cause agglutination in umbilical cord serum, anti-T antibodies are gradually produced in newborns after the first few months of life [1]. Polyagglutination may be inherited or acquired due to infectious or hematologic diseases. Infection has been reported to be the most frequent cause [2,3]. The cause of polyagglutination can be identified by reaction of various lectins with T antigen. The severity of polyagglutination is variable. Here we report a fatal case of polyagglutination in a very low birth weight (VLBW) infant.

CASE PRESENTATION

A very low birth weight female infant was delivered by cesarean section at 30 weeks of gestation due to severe maternal hypertensive disorder of pregnancy. Figure 1 shows the clinical course and laboratory data. Her birth weight was 1,116 g (light for date; the Japanese reference curve for birth weight by gestational age). She was intubated and 120 mg of surfactant was administered for respiratory distress syndrome at birth. Apgar scores were 5 and 9 at 1 and 5 min, respectively. Umbilical artery blood gas measurements were as follows: pH 7.337, pCO₂ 50.8 mmHg, pO₂ 17.0 mmHg, and base excess 0.4 mmol/L.

She was extubated on day 3 and had been doing well on nasal continuous positive airway pressure (PEEP 4-5 cm/H₂O, Flow 8L/min). Apnea occurred on day 9. Minimal bloody stool was observed on day 10, although no abdominal distention was seen on abdominal X-ray. On day 11, she was put on ventilator again due to respiratory acidosis with hematuria. She was transferred to our hospital because of suspected infection and anemia.

On admission, her body temperature was 37.2°C, blood pressure was 54/30 mmHg, heart rate was 193/min, and SpO₂ was 95% on

ventilator (FiO₂ 0.21). No abdominal distention was observed and peristaltic sounds were normal. Laboratory findings suggested an inflammatory response and hemolytic anemia with a coagulation disorder (Table 1). Her blood type was type O, Rh positive, and both direct and indirect Coombs tests were negative. However, immunological screening showed positive red cell polyagglutination. We tested the red cell of baby with only type AB adult plasma to confirm the polyagglutination. A polyagglutination reaction was confirmed between T antigens and various lectins (Table 2). *Arachis hypogea* is in-house prepared, and Glycine soja and *Salva scharea*, and *Salva horminum* are commercially available. (Glycine soja; J-OIL MILLS, INC. *Salva scharea*, and *Salva horminum*; Immucor Gamma).

After workup for sepsis, cefmetazole, fosfomycin, and arbekacin were started. In addition to the administration of antibiotics, washed red blood cells were transfused to address the anemia. 60 U/kg/day of antithrombin and 380 U/kg/day of thrombomodulin were administered. However, fresh frozen plasma (FFP) could not be used due to polyagglutination. Disseminated intravascular coagulation (DIC) and hemorrhagic diathesis progressed rapidly, including gastrointestinal hemorrhage, pulmonary hemorrhage, and nasal bleeding. The patient died on the 12th day of life, on the second day after transfer to our hospital. Methicillin-resistant *Staphylococcus epidermis* and *Corynebacterium jeikeium* were isolated from the skin and pharynx, although blood and cerebrospinal fluid cultures were both negative. Autopsy findings revealed mild histological necrotizing enterocolitis (NEC) from the descending colon to the sigmoid colon. The finding of the lung showed pulmonary edema and hemorrhage due to DIC. Brain was not investigated.

DISCUSSION

Polyagglutination is a rare condition in which cryptic T antigens on the red blood cell membrane react with adult serum. We routinely checked polyagglutination screening at Department of Transfusion and Cell Biology in our hospital, because we

Correspondence to: Naoshi Yamada, Department of Obstetrics and Gynecology, University of Miyazaki Hospital, 5200 Kihara, Kiyotake-cho, Miyazaki City, Miyazaki 889-1692, Japan, Tel: +810985850988; Fax: +810985856149; E-mail: naoshi_yamada@med.miyazaki-u.ac.jp

Received: January 15, 2021, **Accepted:** February 23, 2021, **Published:** March 03, 2021

Citation: Yamada N, Kodama Y, Goto T, Yamashita R, Doi K, Kaneko M, et al. (2021) A Very Low Birth Weight Infant with Severe Red Blood Cell Polyagglutination: A Case Report. J Neonatal Biol. 10:287

Copyright: © 2021 Yamada N, et al. This is an open-access article distributed under the terms of the Creative Commons Attribution License, which permits unrestricted use, distribution, and reproduction in any medium, provided the original author and source are credited.

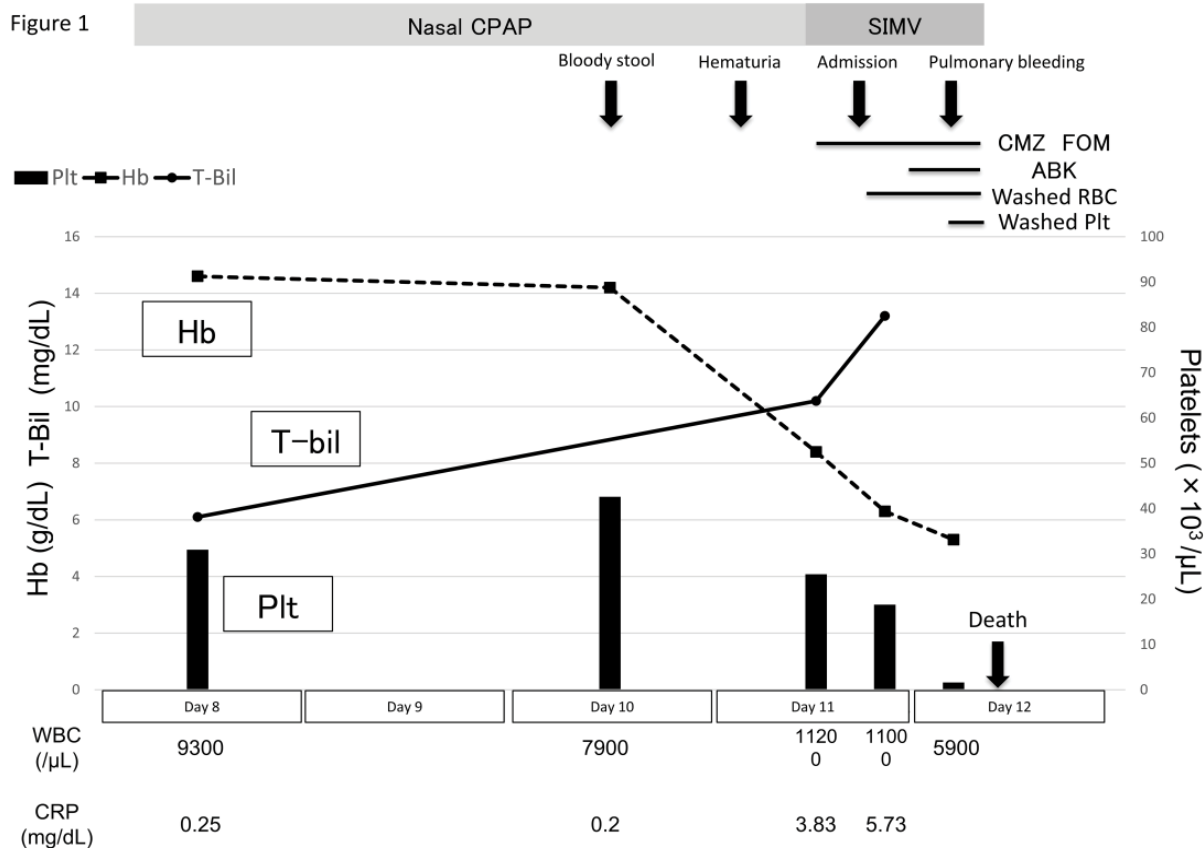


Figure 1: Clinical course and laboratory data.

Table 1: Laboratory data on admission.

Complete blood count		Chemistry		Coagulation	
WBC	11,100/μL	T-Bil	13.2 mg/dL	aPTT	106.6 s
Stab	17	D-Bil	0.5 mg/dL	PT-INR	8.59
Seg	8	AST	573 U/L	Fib	88 mg/dL
Lymph	60	ALT	19 U/L	AT-III	0.16
Mono	7	LDH	7455 U/L	D-dimer	7.46 μg/mL
Eosino	8	BUN	22.3 mg/dL		
RBC	2.59 × 10 ⁶ /μL	Cre	0.4 mg/dL		
Hb	6.3 g/dL	Na	125 mmol/L	Blood transfusion test	
Hct	0.196	K	6.6 mmol/L	Blood type	O Rh (+)
Plt	188 × 10 ³ /μL	Cl	98 mmol/L	Direct Coombs	negative
		CRP	5.73 mg/dL	Indirect Coombs	negative
		PCT	21.8 mg/mL	Polyagglutination	positive

ALT: Alanine Transaminase; APTT: Activated Partial Thromboplastin Time; AST: Aspartate Aminotransferase; AT-III: Antithrombin III; BUN: Blood Urea Nitrogen; CRP: C-reactive Protein; D-Bil: Direct Bilirubin; Fib: Fibrinogen; Hb: Hemoglobin; Hct: Hematocrit; PCT: Procalcitonin; Plt: Platelet; PT-INR: Prothrombin Time Test-International Normalized Ratio; RBC: Red Blood Cells; T-Bil: Total Bilirubin; WBC: White Blood Cells.

Table 2: Classification of erythrocyte polyagglutination.

Lectins	Adult		Polyagglutination				Present case Red blood cell
	Red blood cell	T	Tn	Tk	Th	Cad	
Normal adult blood plasma	0	+	+	+	+	+	1+
<i>Arachis hypogea</i>	0	+	0	+	+	0	4+
(enzyme treated)		+		++	0/w [§]		0
<i>Glycine soja</i>	0	+	+	0	0	0/+	0
<i>Salva scharea</i>	0	0	+	0	0	0	0
<i>Salva hominum</i>	0	0	+	0	0	+	0
1% polybrene	+	0	w [§]	+	+	+	0

§; Weak reaction

previously experienced two cases of polyagglutination. In neonatal medicine, polyagglutination has been reported to be associated with infectious diseases, especially NEC [3]. One prospective study reported that 27% of infants with NEC had polyagglutination [4]. The degree of antigen exposure was reported to be associated with severity of NEC [3,4]. In the present case, hemolytic anemia due to polyagglutination and DIC progressed rapidly, leading to death. NEC was not recognized by macroscopic examination at autopsy but was revealed histologically. *Clostridium perfringens* has been reported to be a causative agent of polyagglutination in NEC [5,6]. This organism produces neuraminidase, which destroys the red blood cell membrane, leading to exposure of the sugar chain antigens on RBCs. In our case, methicillin-resistant *S. epidermidis*, but not *C. perfringens*, was isolated from the patient's pharynx, skin, and fecal cultures.

Pathological autopsy revealed a small number of Gram-positive bacilli on the mucosal and serosal surfaces of the sigmoid and descending colon, without an inflammatory reaction. Therefore, NEC was not likely to be due to these Gram-positive bacilli. Azan staining showed widespread submucosal fibrosis, so we speculate that the cause of NEC was ischemia of the digestive tract. In previous reports, polyagglutination in newborns was often caused by NEC. However, the NEC in our case was histologically mild.

We speculate that polyagglutination due to infection could result in circulatory failure and intestinal ischemia, consistent with the findings of Azan staining. Based on the above findings, our case was considered to have polyagglutination with histologically mild NEC, rather than microscopically obvious NEC. Exchange transfusion is one of the treatment options for polyagglutination. Conventionally, administration of FFP is contraindicated in cases of polyagglutination as it may lead to T activation and hemolysis. When FFP is clinically indicated, low-titer anti-T antibody FFP may be used instead [7]. However, some reports have noted that patients with polyagglutination do not always develop hemolytic anemia [2], and that exchange transfusion using normal FFP, rather than low-titer anti-T antibody FFP, can be life-saving [5]. Moh-Klaren et al. noted that avoiding use of coagulation factors or FFP due to fear of further hemolysis may lead to worsening of symptoms [5]. Alternatives to FFP include washed preparations of red blood cells and platelets [7]. All fractionated blood products (e.g., coagulation factor concentrates such as II/VII/IX/X concentrates, albumin, and intravenous immunoglobulin) and recombinant concentrates (e.g. rVIIa, NovSeven, FVIII, Recombinate/Kogenate, FIX Recombinine) may also be used in cases of polyagglutination [8]. Exchange transfusion could remove circulating factors, such as enzymes and red blood cell antigens [9]. Therefore, exchange transfusion should be considered in cases of polyagglutination.

CONCLUSION

In conclusion, severe polyagglutination can occur even with mild NEC, resulting in hemolytic anemia and DIC. In addition, although polyagglutination is conventionally a contraindication to the administration of FFP, patients can potentially be saved by exchange transfusion using low-titer anti-T antibody FFP. Neonates with NEC should be screened for polyagglutination before transfusing plasma or platelet to avoid hemolysis.

ACKNOWLEDGMENTS

The authors are grateful to Drs. Kubuki and Takenouchi, Department of Transfusion and Cell Biology, Miyazaki University, for providing clinical assistance.

FUNDING

This report was supported by a Grant for Clinical Research from Miyazaki University (2019).

CONFLICTS OF INTEREST

The authors declare that they have no conflict of interest.

REFERENCES

1. Wilson J. A review of serologic problems caused by polyagglutinable red cells. *Am J Med Technol.* 1977;43:147-155.
2. Harvey GK, David JA. Mollison's blood transfusion in clinical medicine. *Med J Armed Forces India.* 2005;62(2):204.
3. Marshall LR, Barr AL, French NP, Lown JA, Knowles S. A fatal case of necrotizing enterocolitis in a neonate with polyagglutination of red blood cells. *J Paediatr Child Health.* 1993;29(1):63-65.
4. Klein RL, Novak RW, Novak PE. T-cryptantigen exposure in neonatal necrotizing enterocolitis. *J Pediatr Surg.* 1986;21(12):1155-1158.
5. Moh-Klaren J. Severe hemolysis after plasma transfusion in a neonate with necrotizing enterocolitis, *Clostridium perfringens* infection, and red blood cell T-polyagglutination. *Transfusion.* 2017;57(11):2571-2577.
6. Seger R. Necrotizing enterocolitis and neuramidase-producing bacteria. *Acta Paediatr.* 1980;35(2):121-128.
7. New HV, Berryman J, Bolton-Maggs PH, Cantwell C, Chalmers EA, Davies T, et al. Guidelines on transfusion for fetuses, neonates and older children. *Br J Haematol.* 2016;175(5):784-828.
8. Massey E. Diagnosis and management of T-antigen activation. *NHS Blood and Transplant Specification* 2011.
9. Crookston KP, Reiner AP, Cooper LJM, Sacher RA, Blajchman MA, Heddle NM. RBC T activation and hemolysis: implications for pediatric transfusion management. *Transfusion.* 2000;40(7):801-812.